

Fotografie tratte dai preparati
di Anatomia Microscopica
(2a parte)

Corso di Elementi di Anatomia Umana
Corso di Laurea in Scienze Biologiche

Docente Dr. Vittorio Bertone

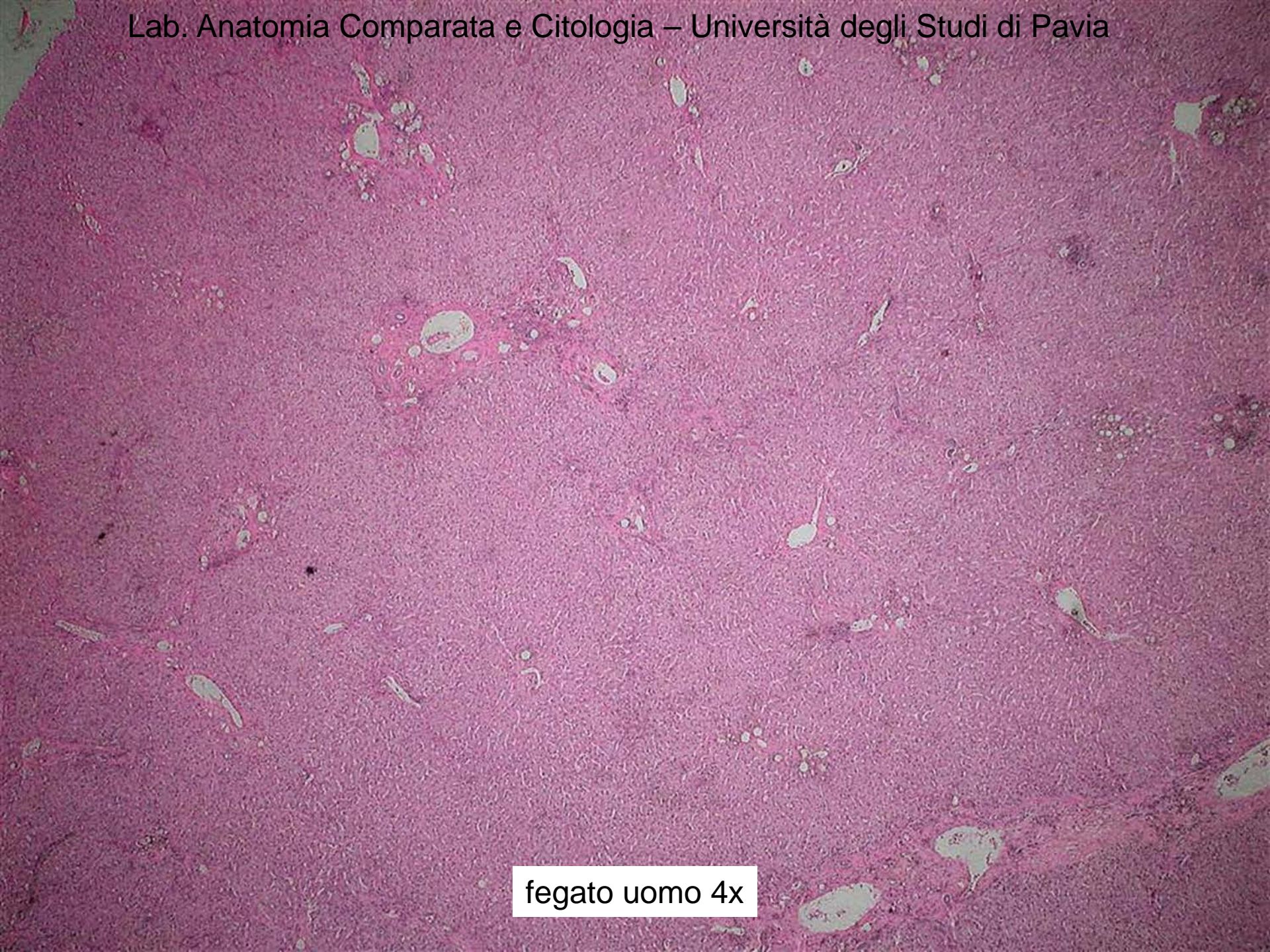
Laboratorio di Anatomia Comparata e Citologia
Dipartimento di Biologia e Biotecnologie "L. Spallanzani"
Università di Pavia

WARNING!

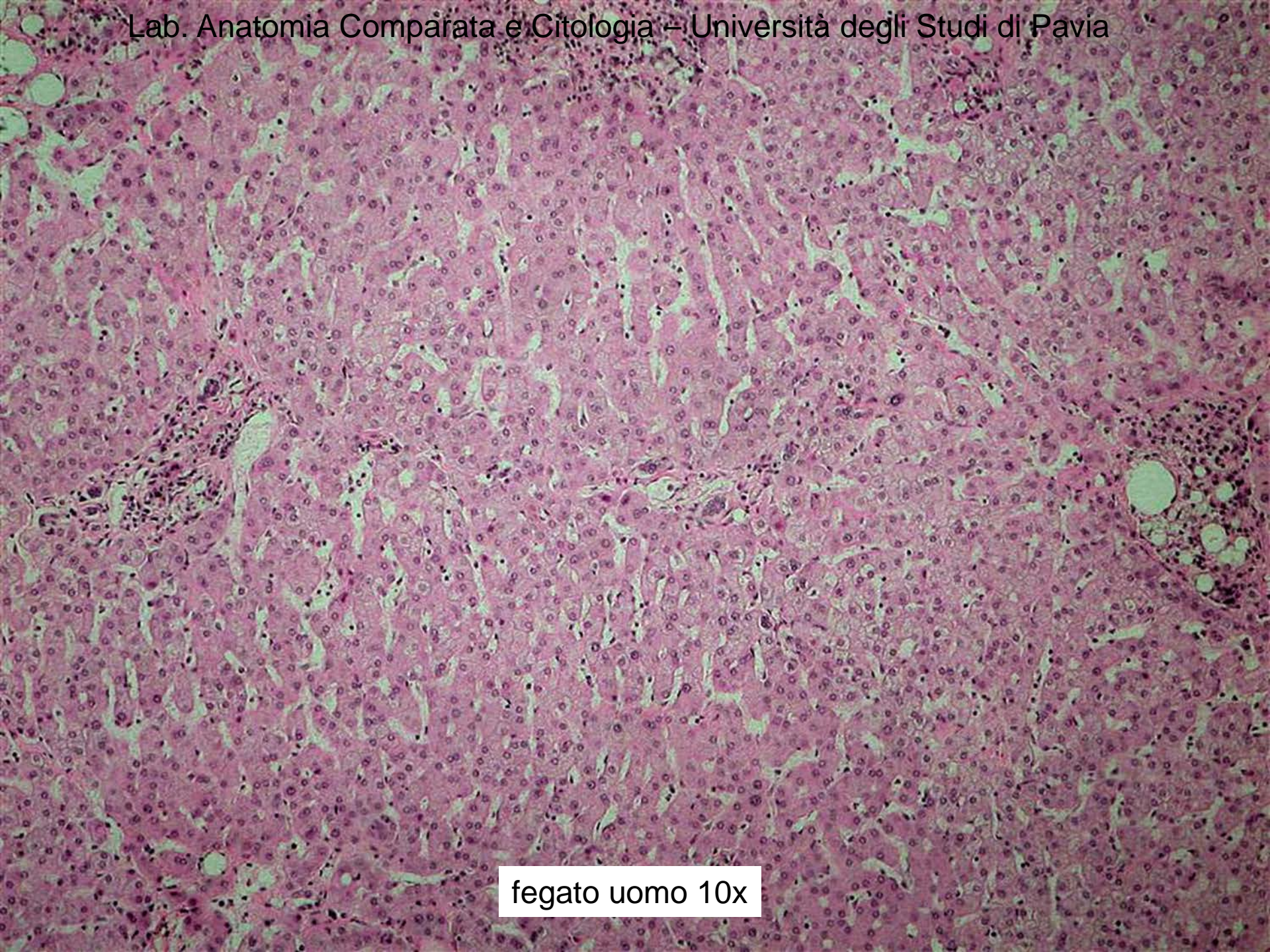
Questo materiale è concesso ad esclusivo uso didattico per gli studenti del corso di Elementi di Anatomia Umana – Corso di Laurea in Scienze Biologiche – Università degli Studi di Pavia

Docente: Prof. Vittorio Bertone

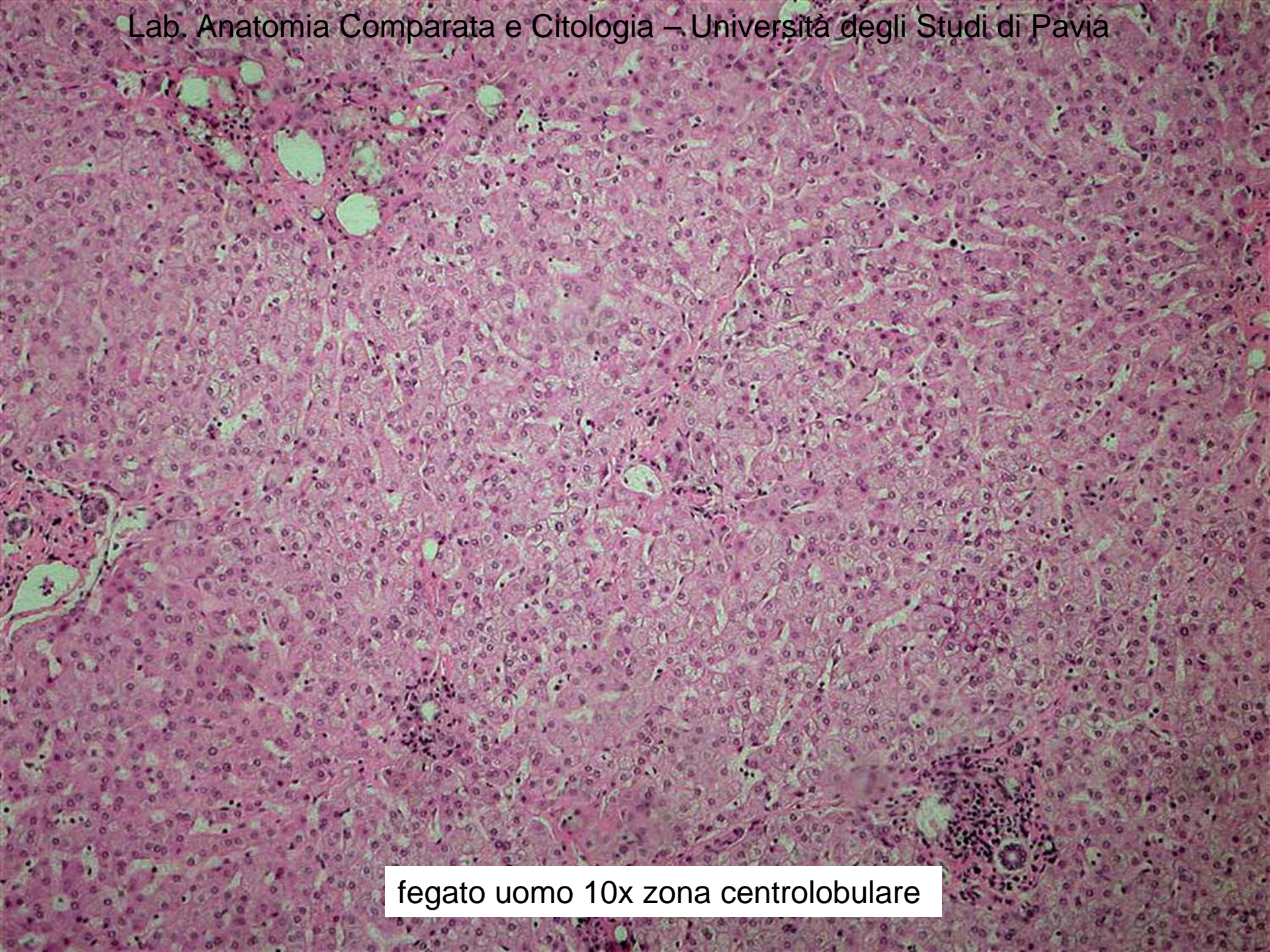
Ogni altro uso è espressamente vietato e sarà perseguito a norma di legge



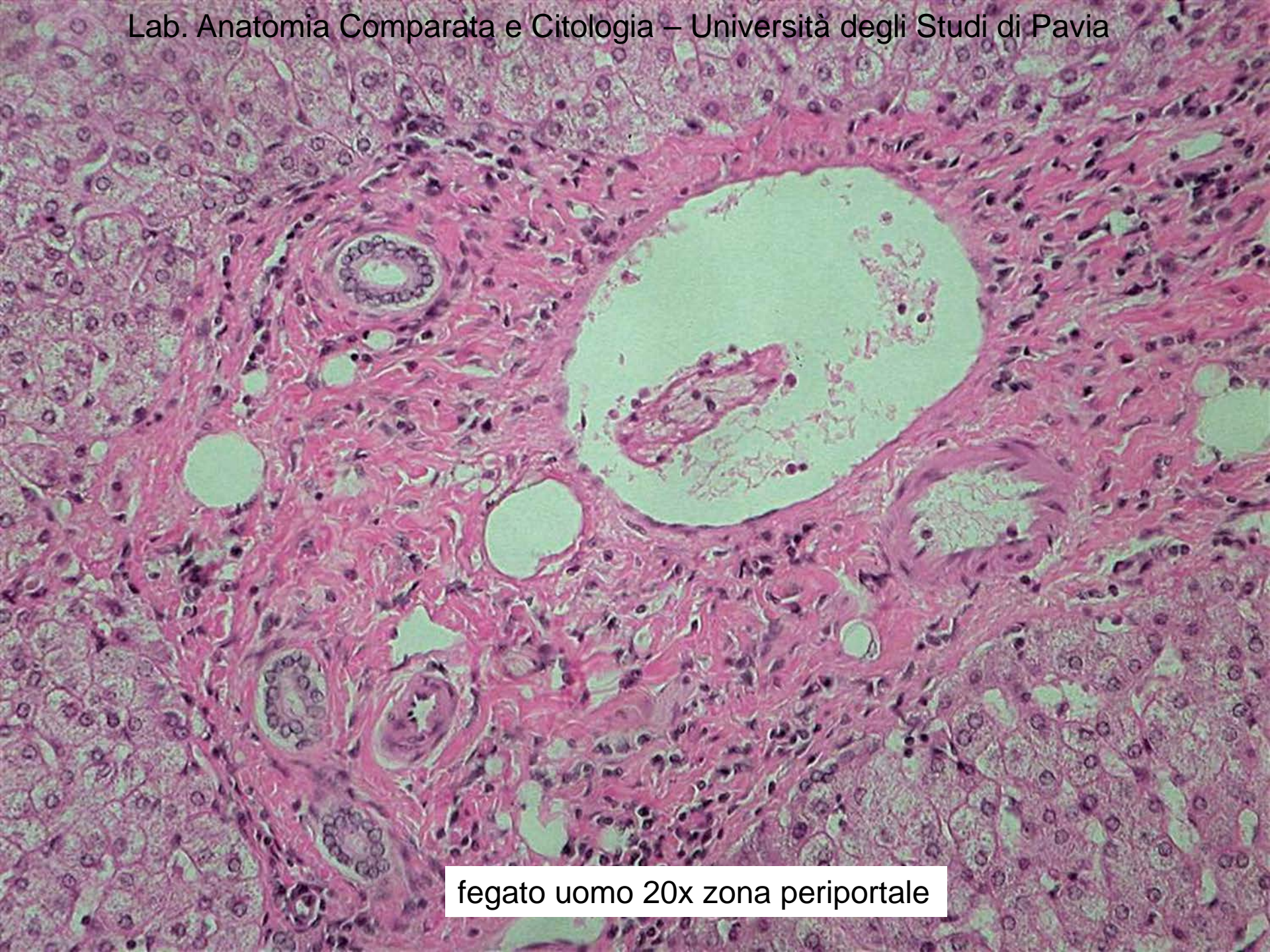
fegato uomo 4x



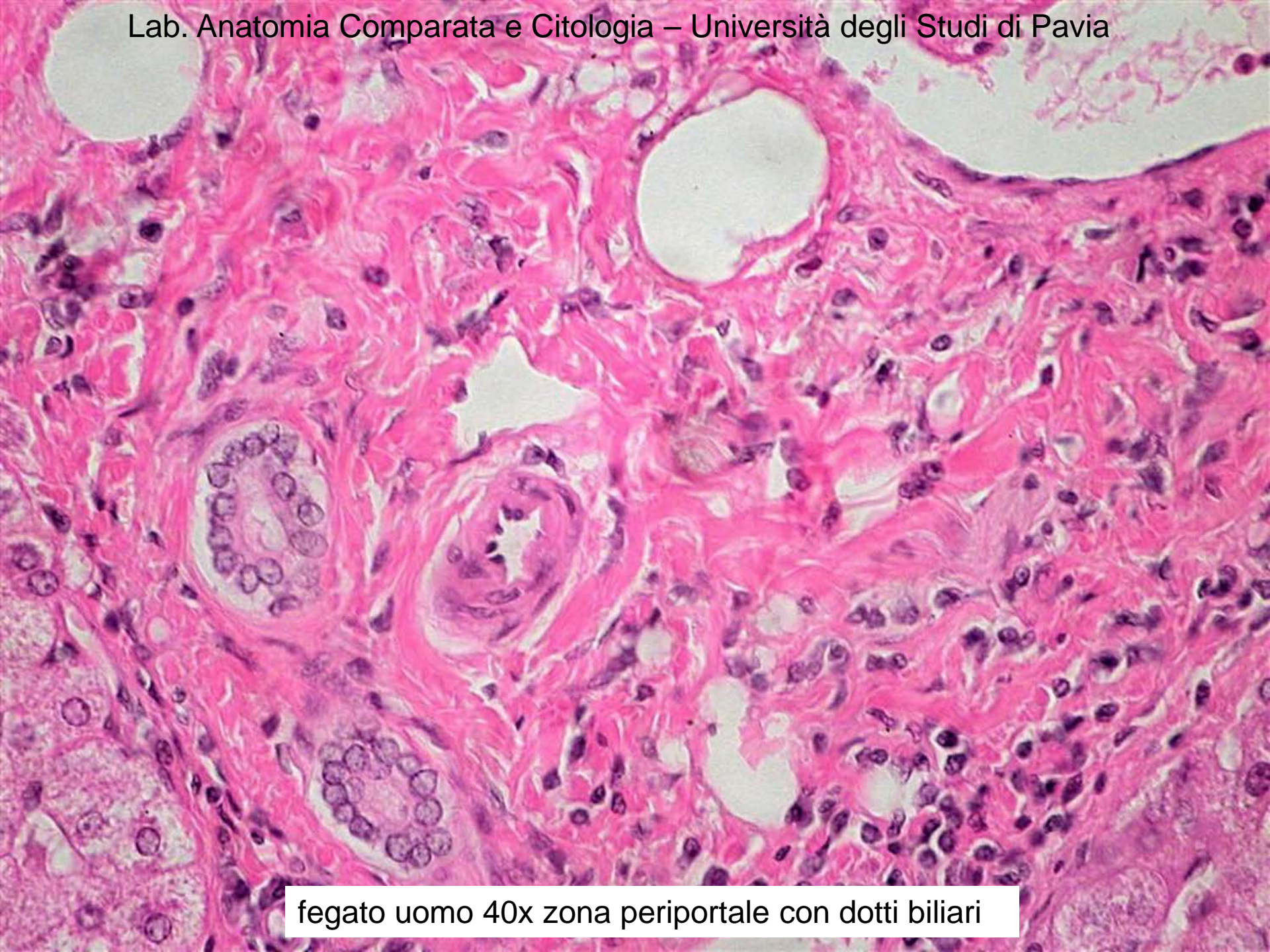
fegato uomo 10x



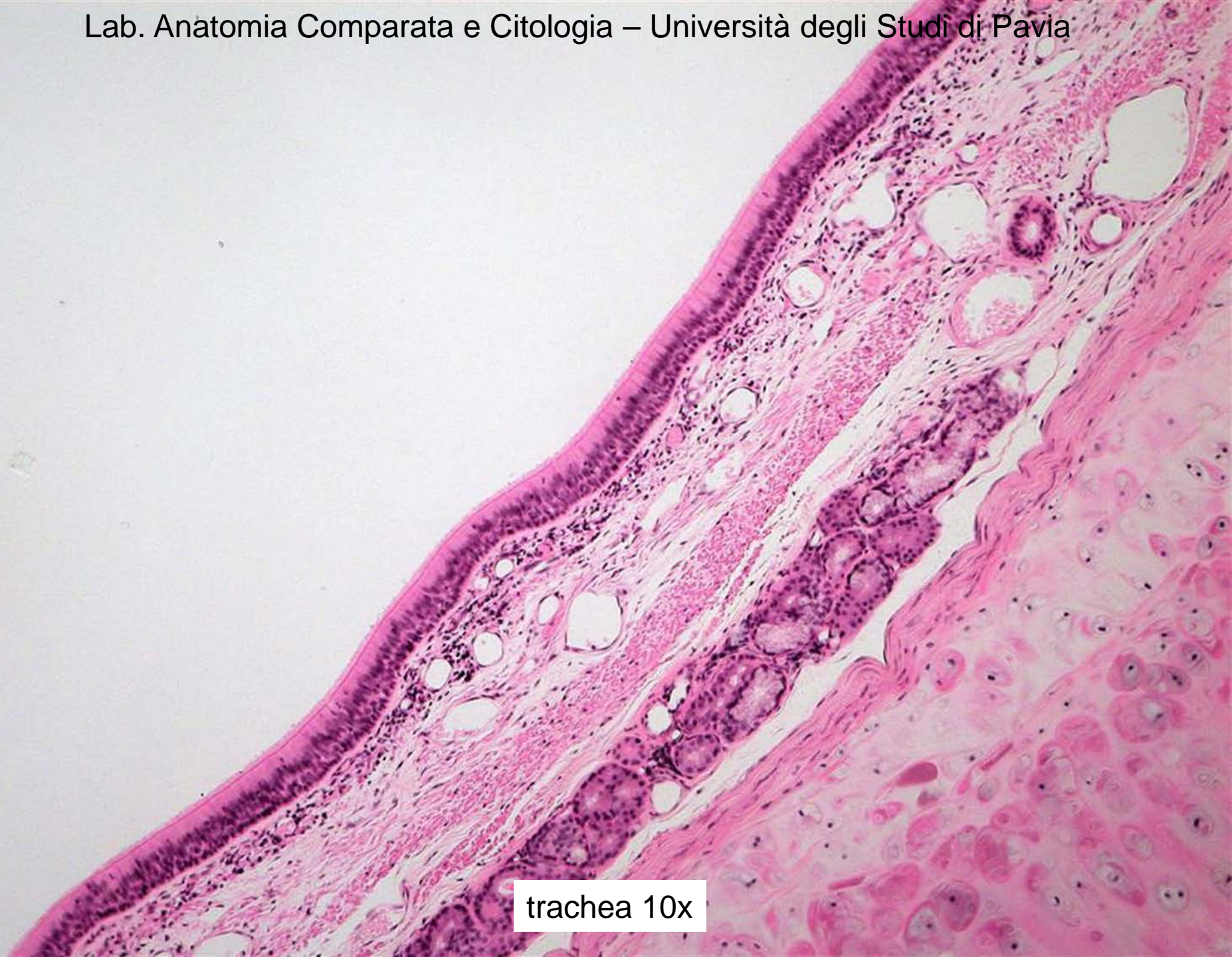fegato uomo 10x zona centrolobulare



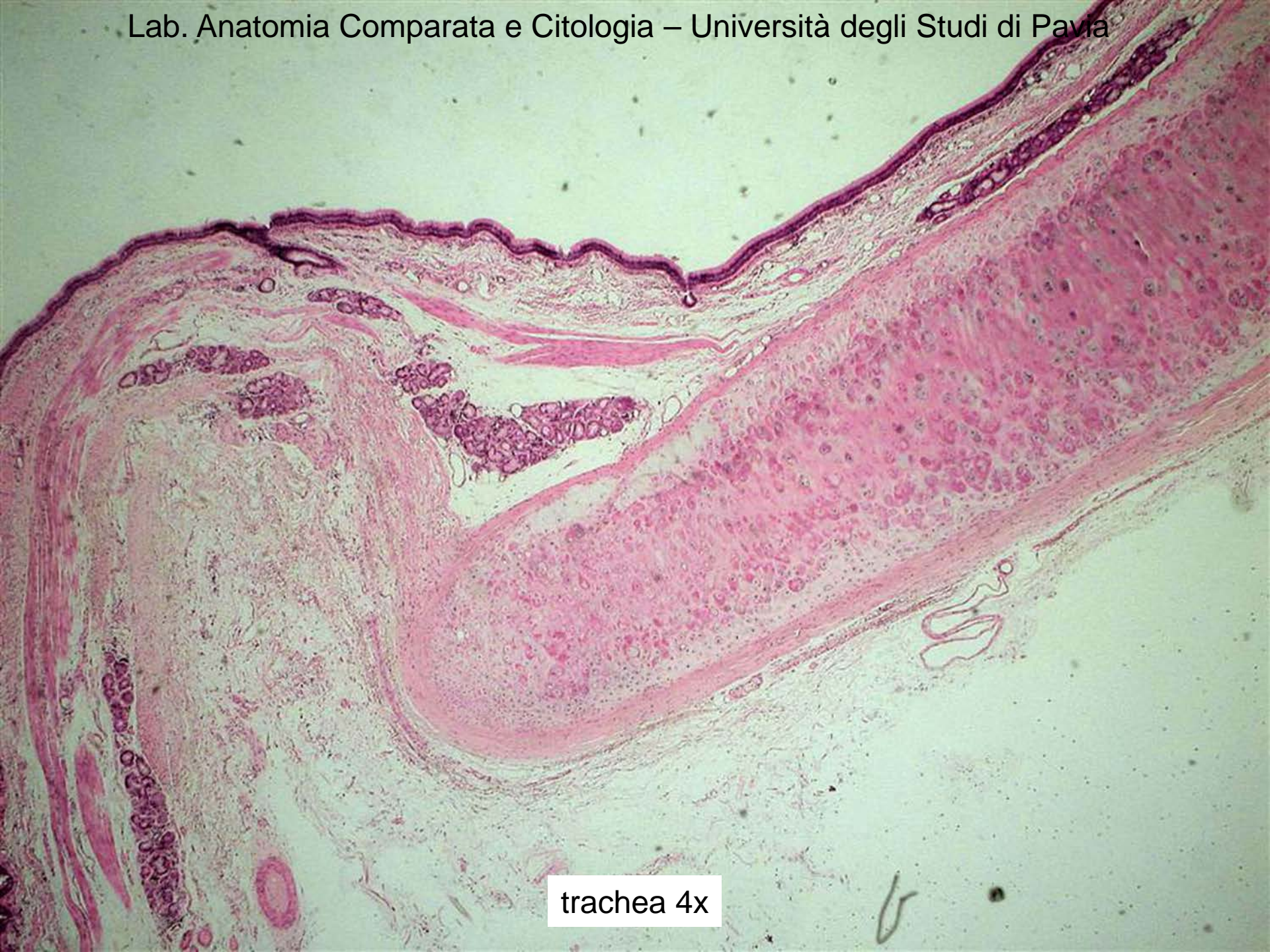
fegato uomo 20x zona periportale



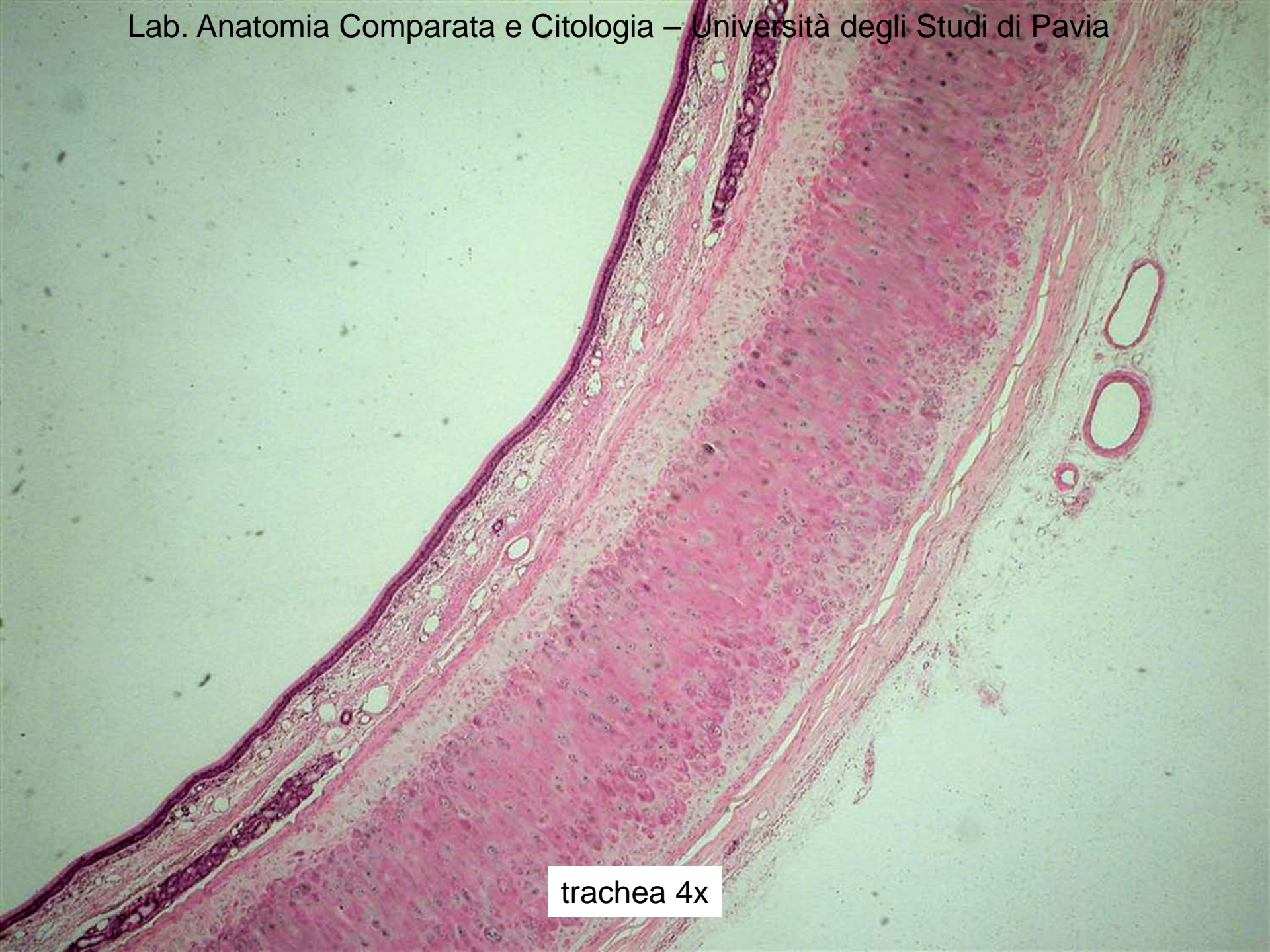
fegato uomo 40x zona periportale con dotti biliari



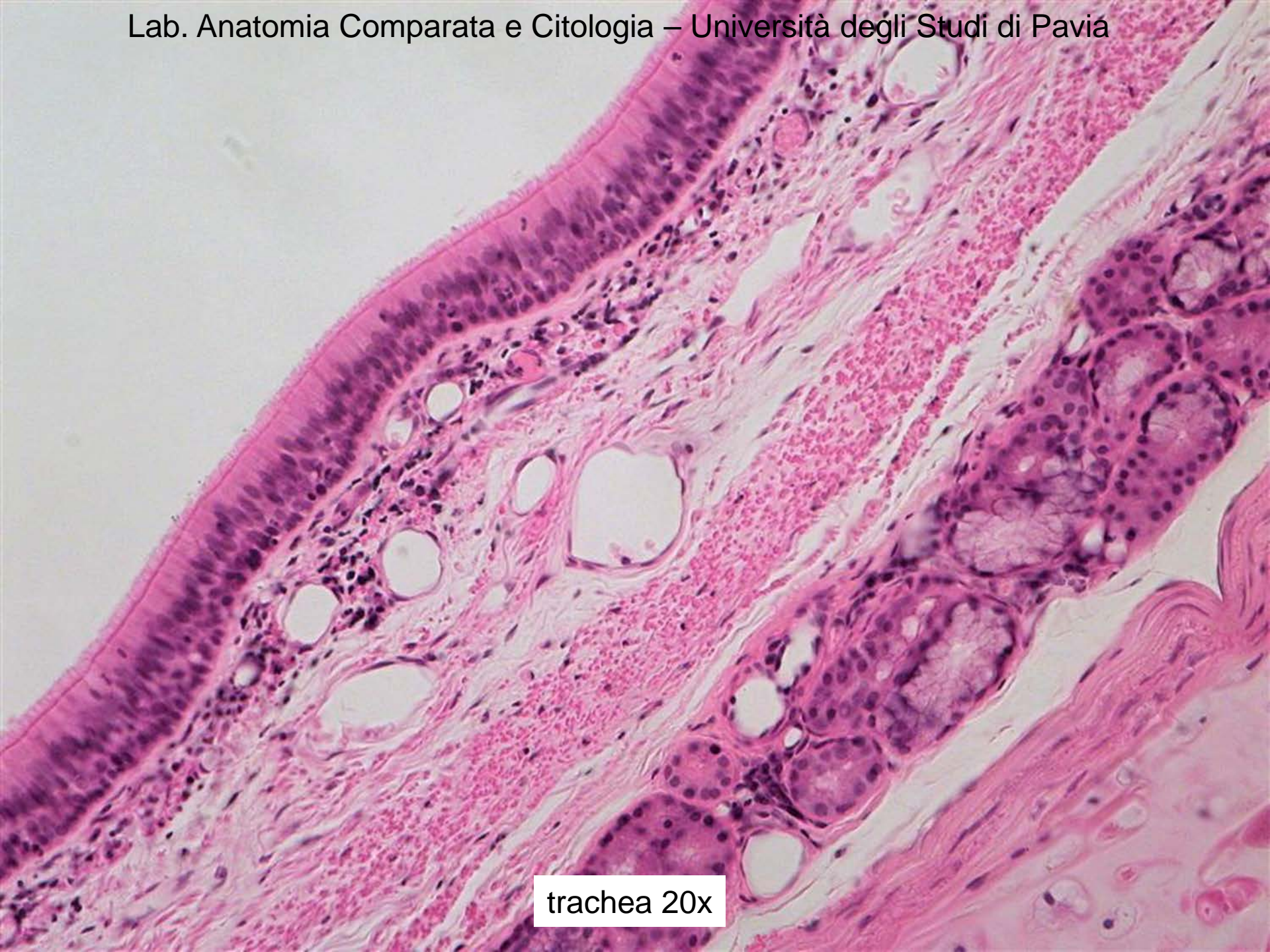trachea 10x



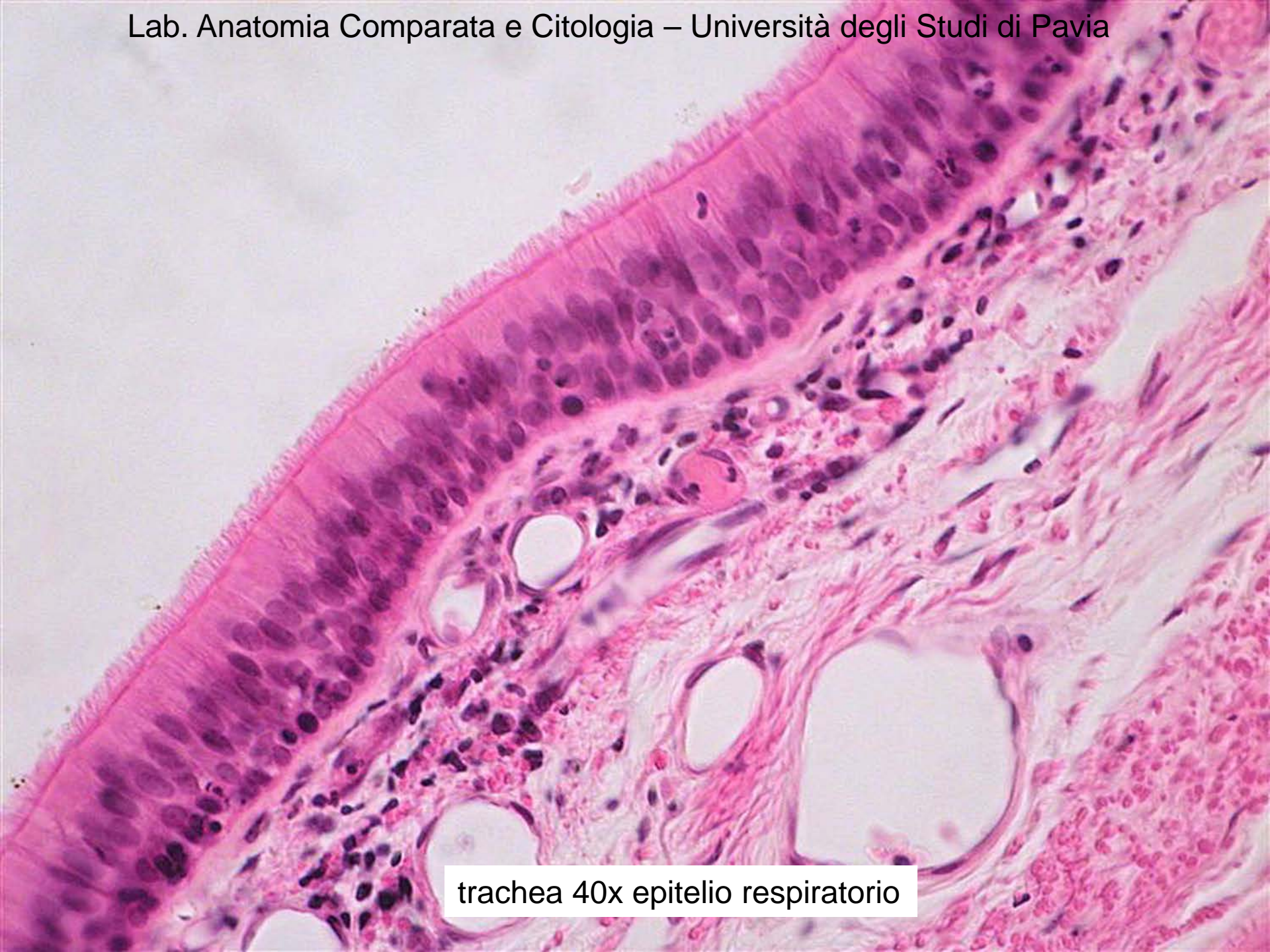trachea 4x



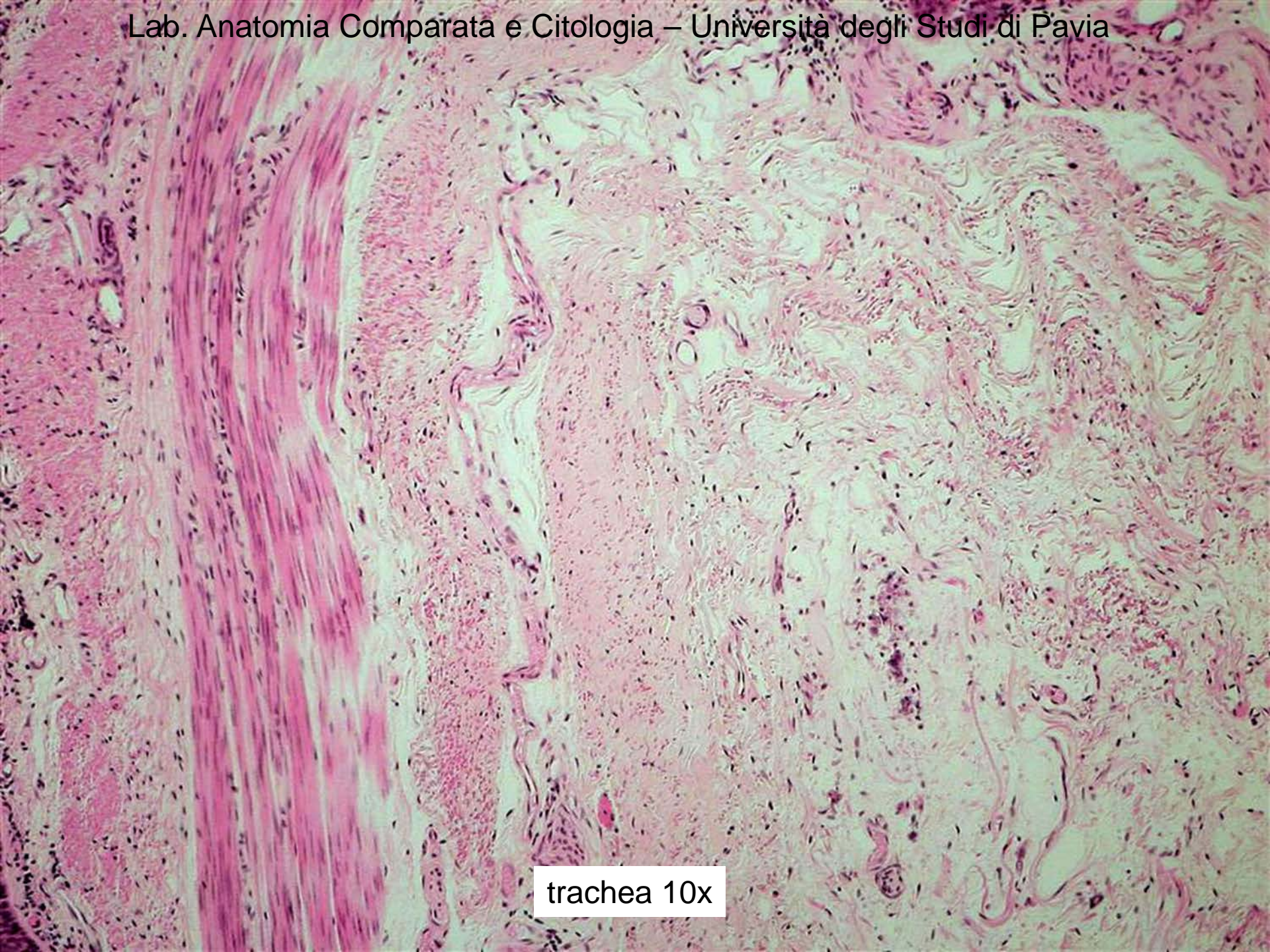
trachea 4x



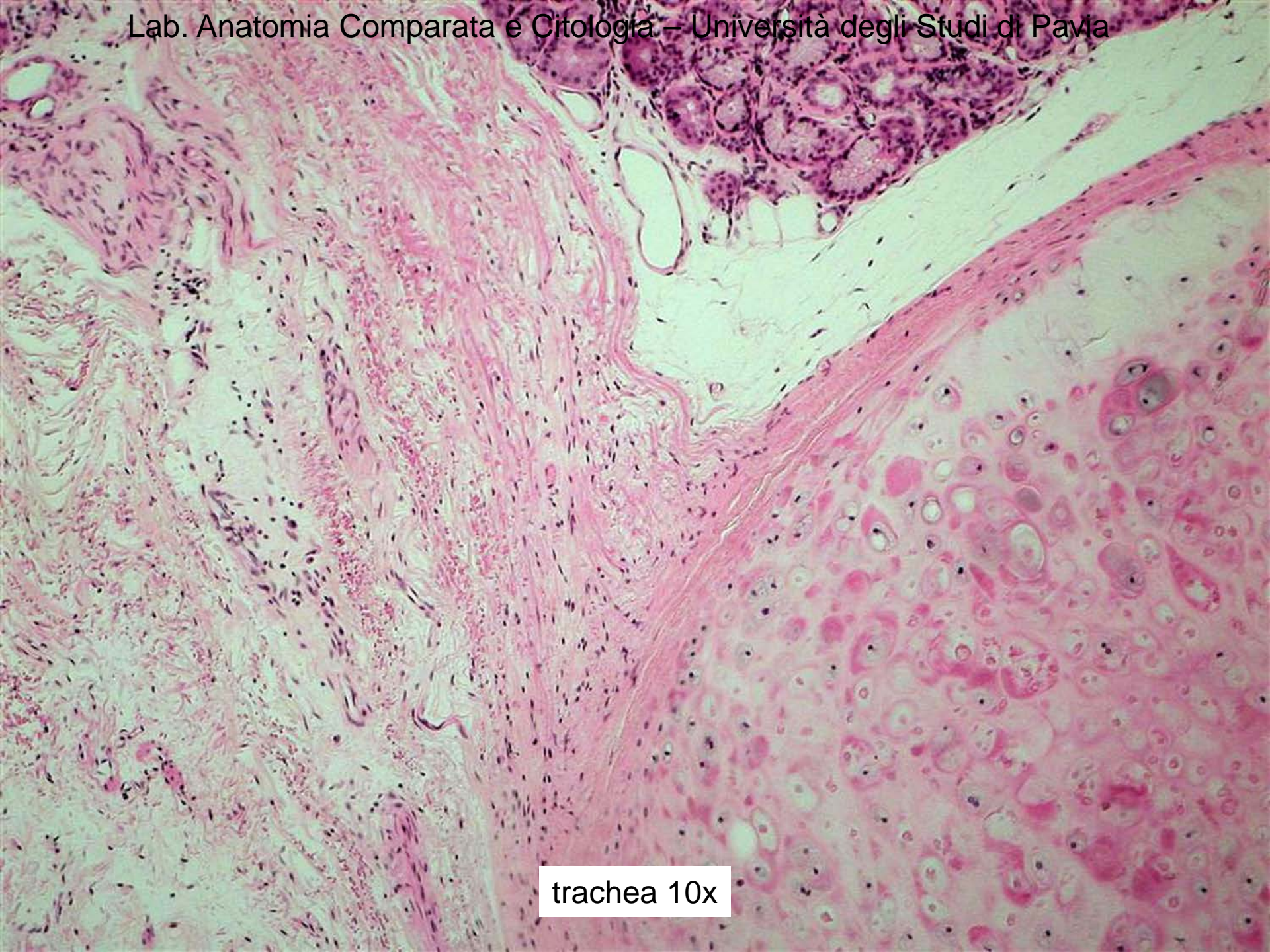trachea 20x



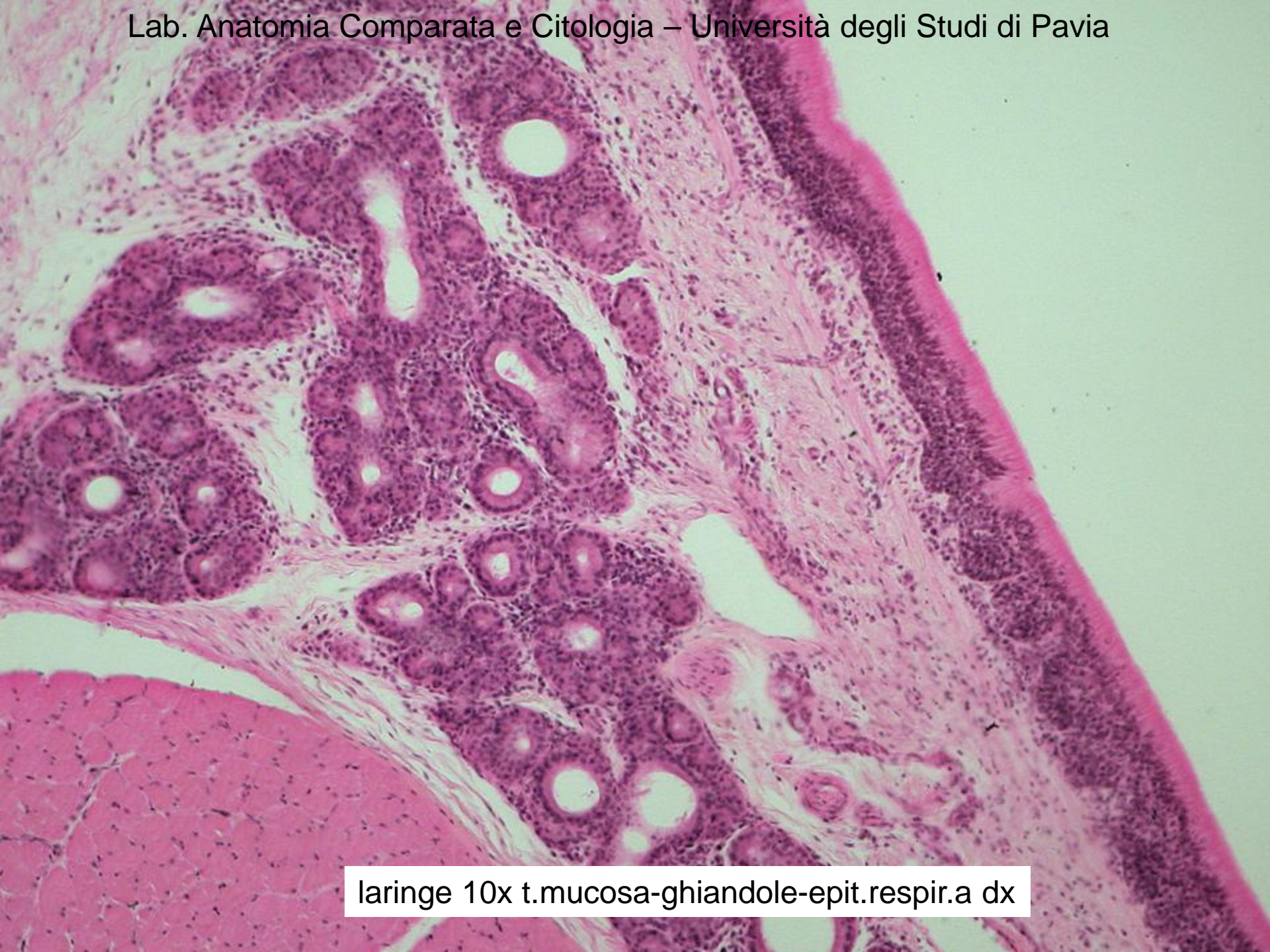
trachea 40x epitelio respiratorio



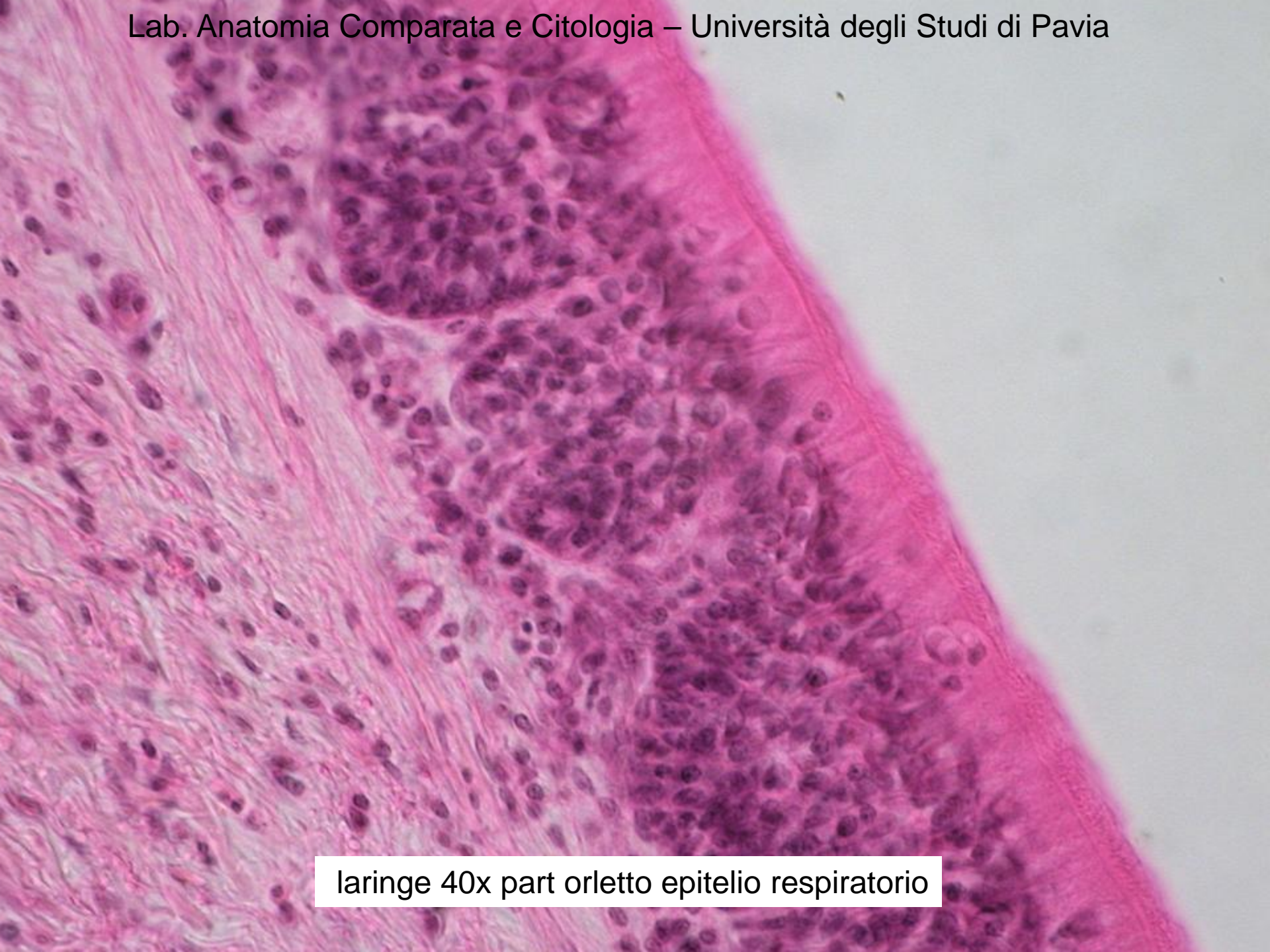trachea 10x



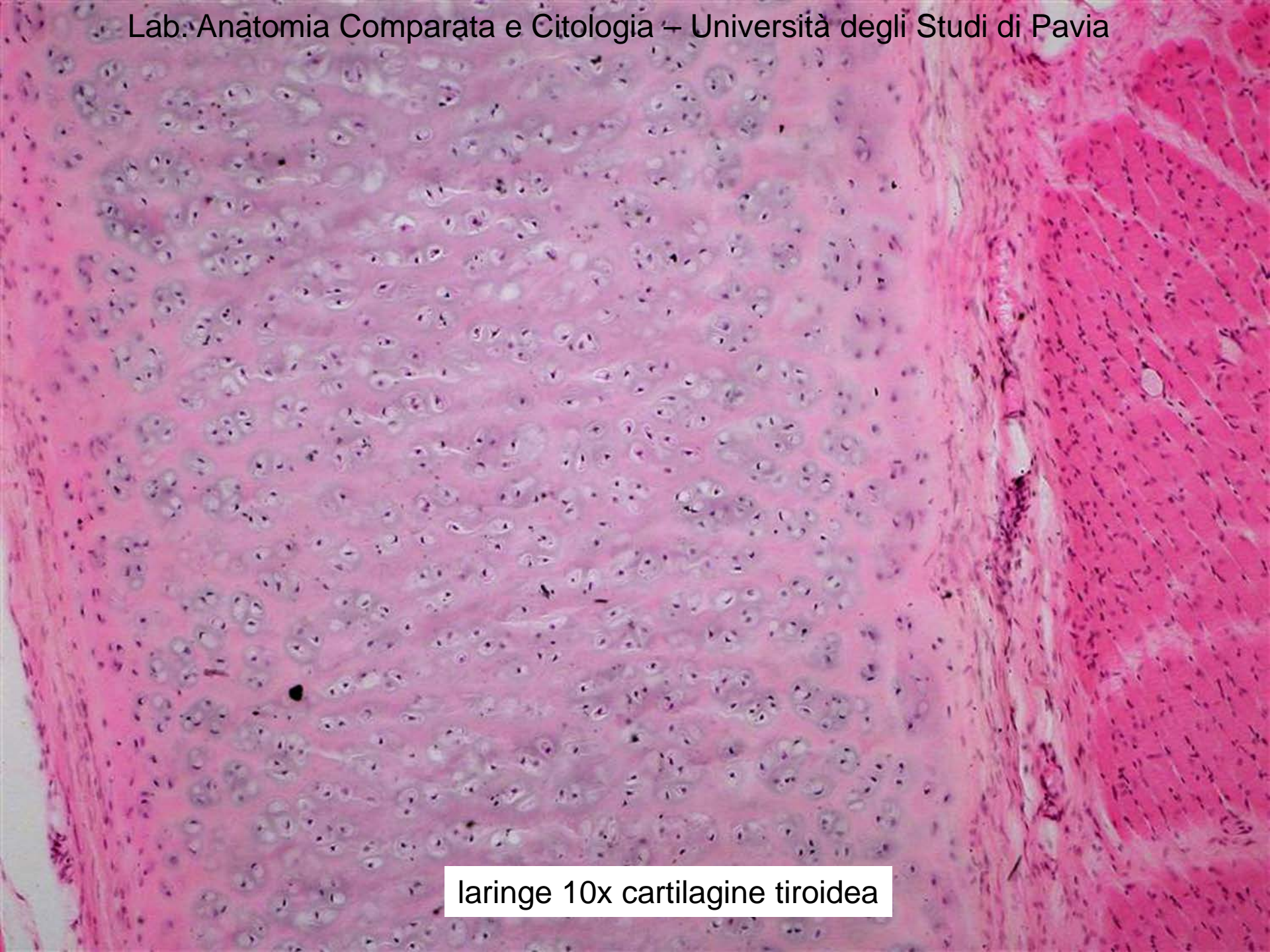
trachea 10x



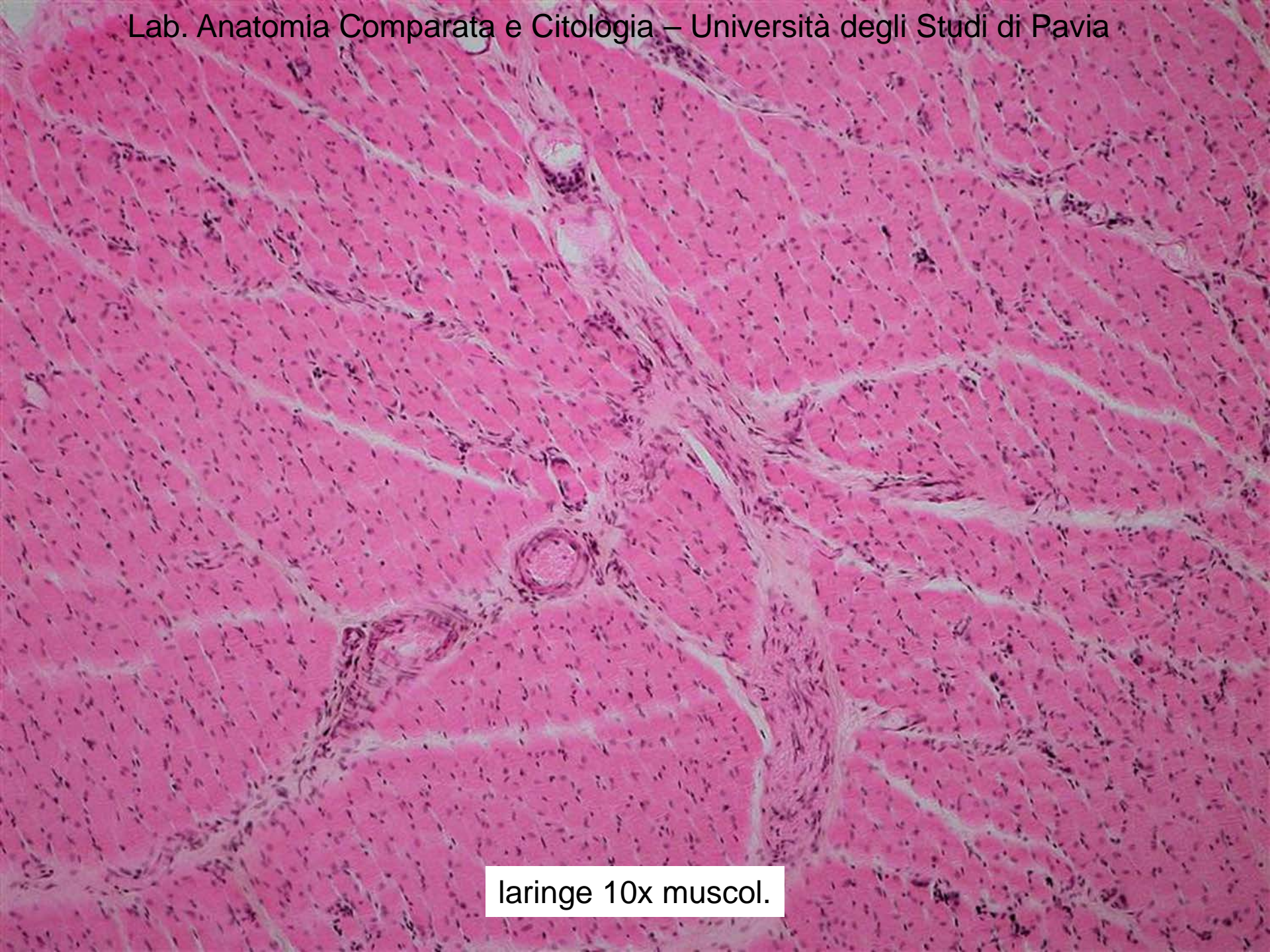
laringe 10x t.mucosa-ghiandole-epit.respir.a dx



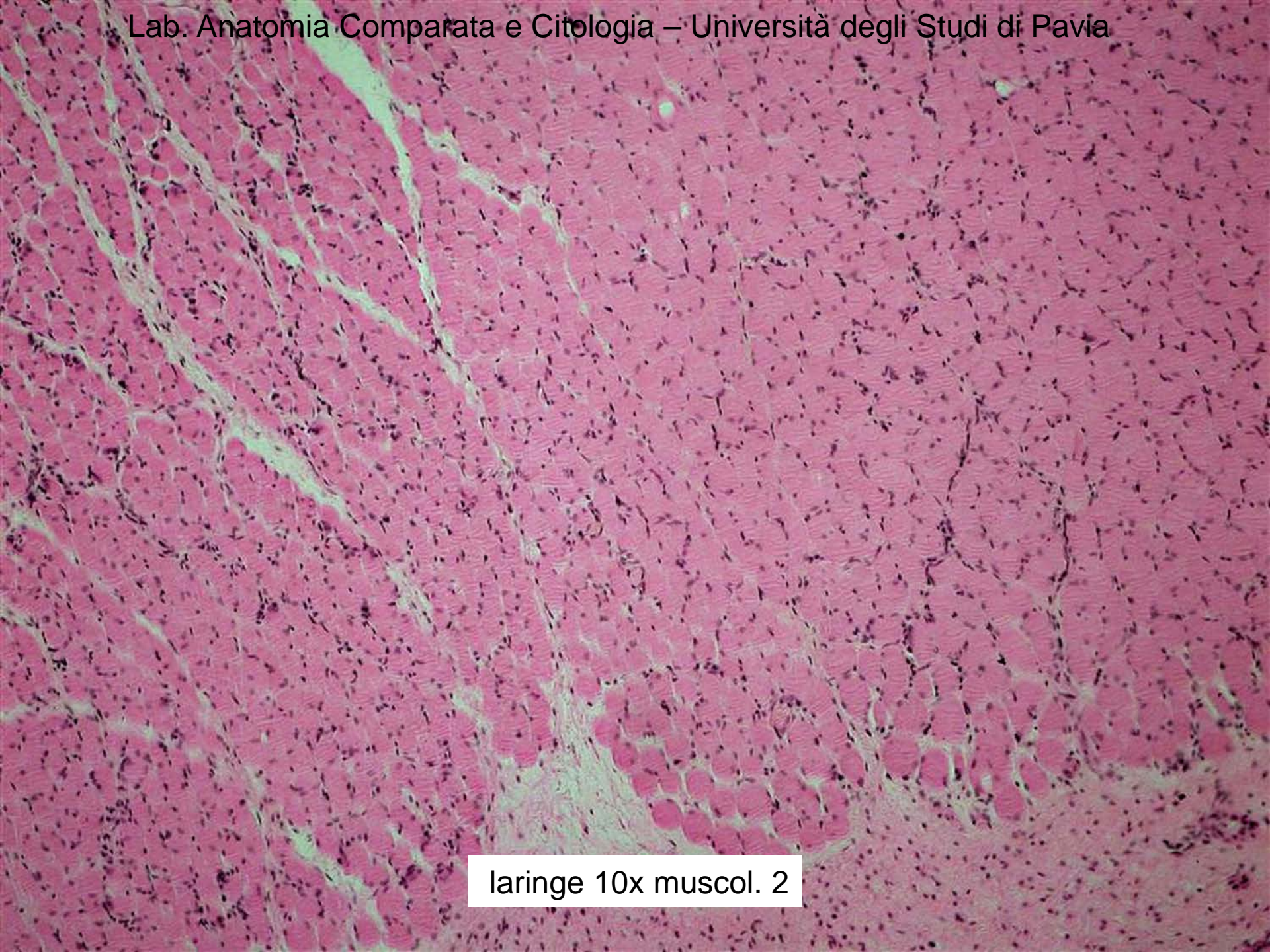
laringe 40x part orletto epitelio respiratorio



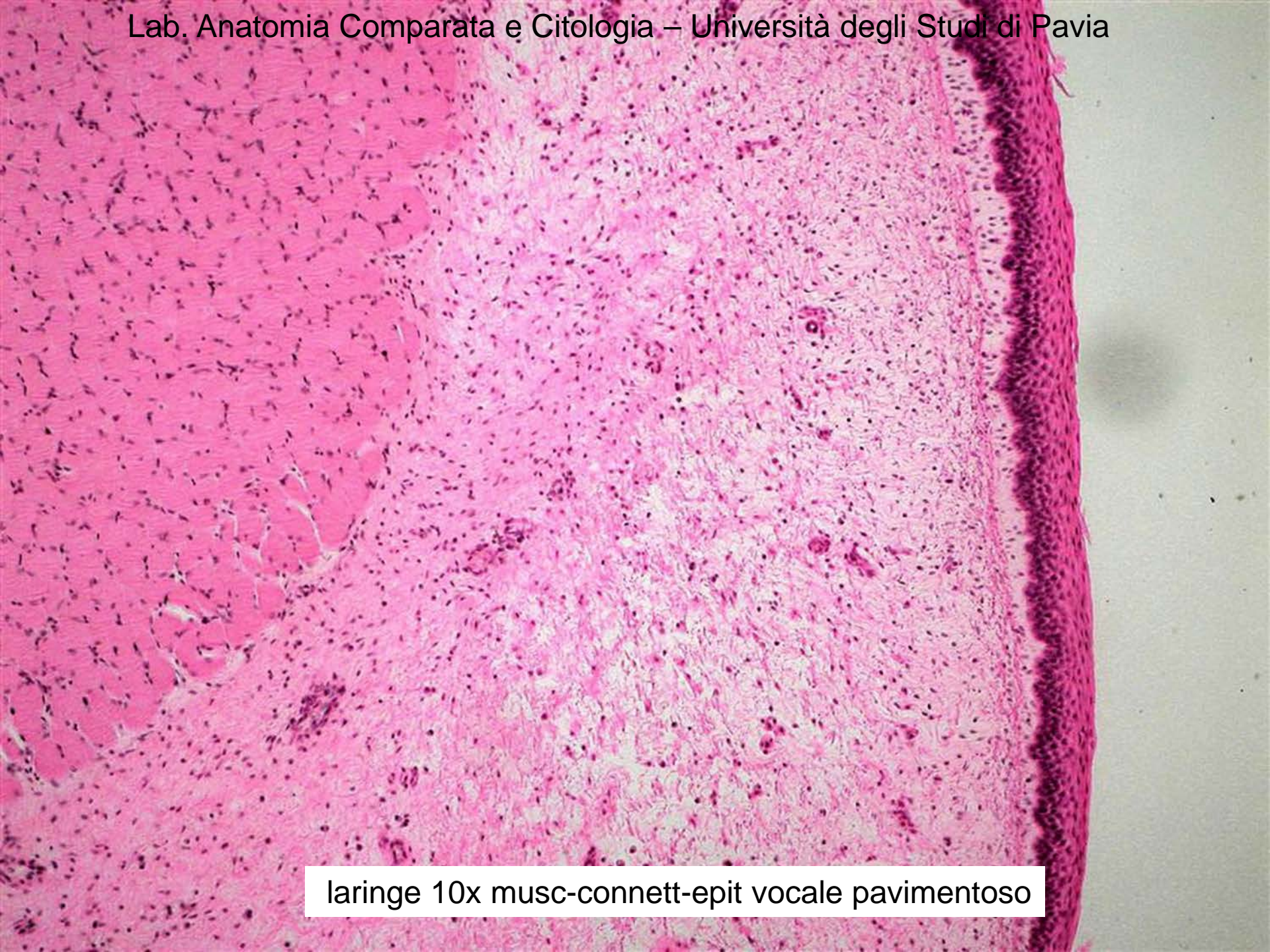laringe 10x cartilagine tiroidea



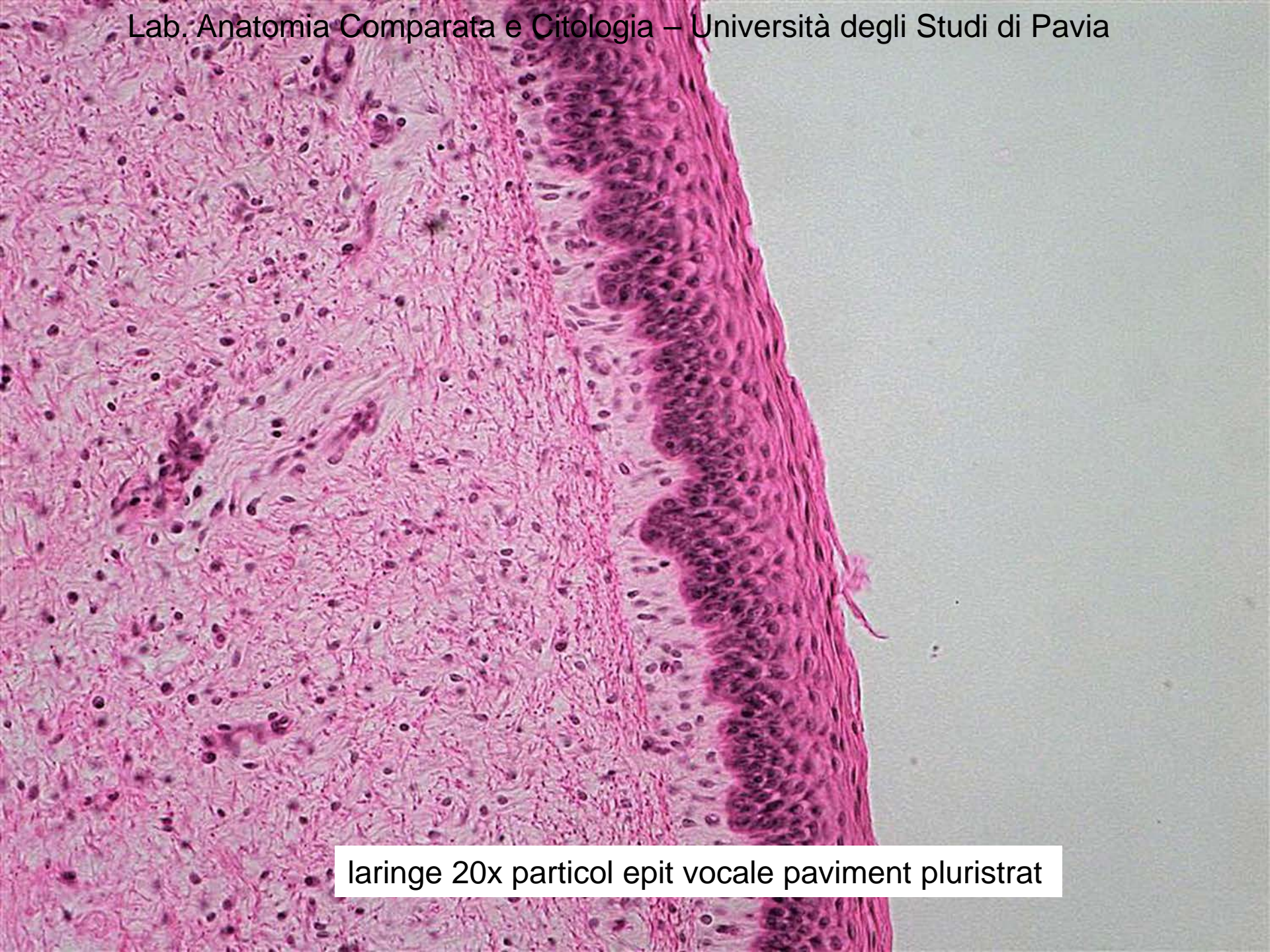
laringe 10x muscol.



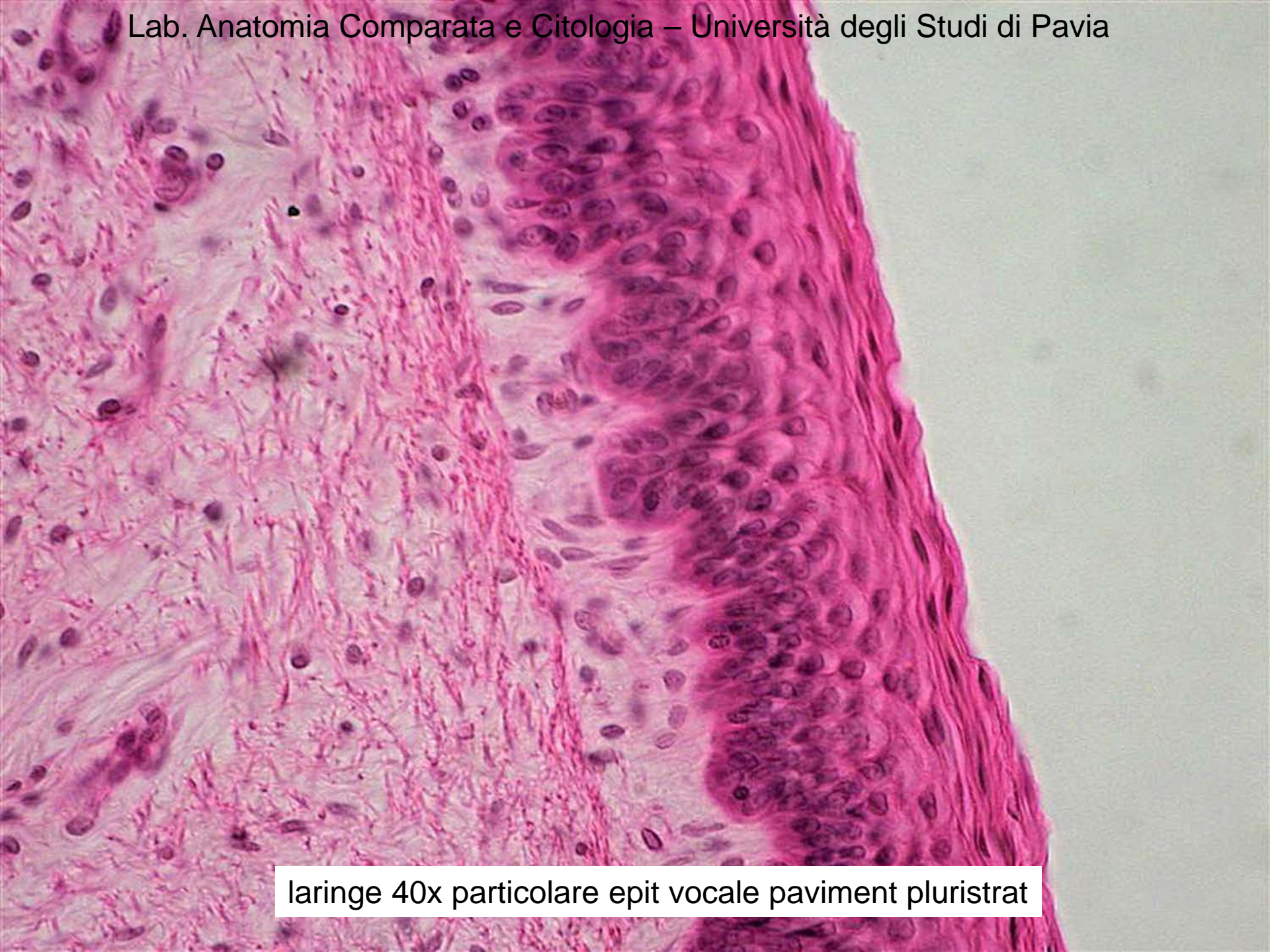
laringe 10x muscol. 2



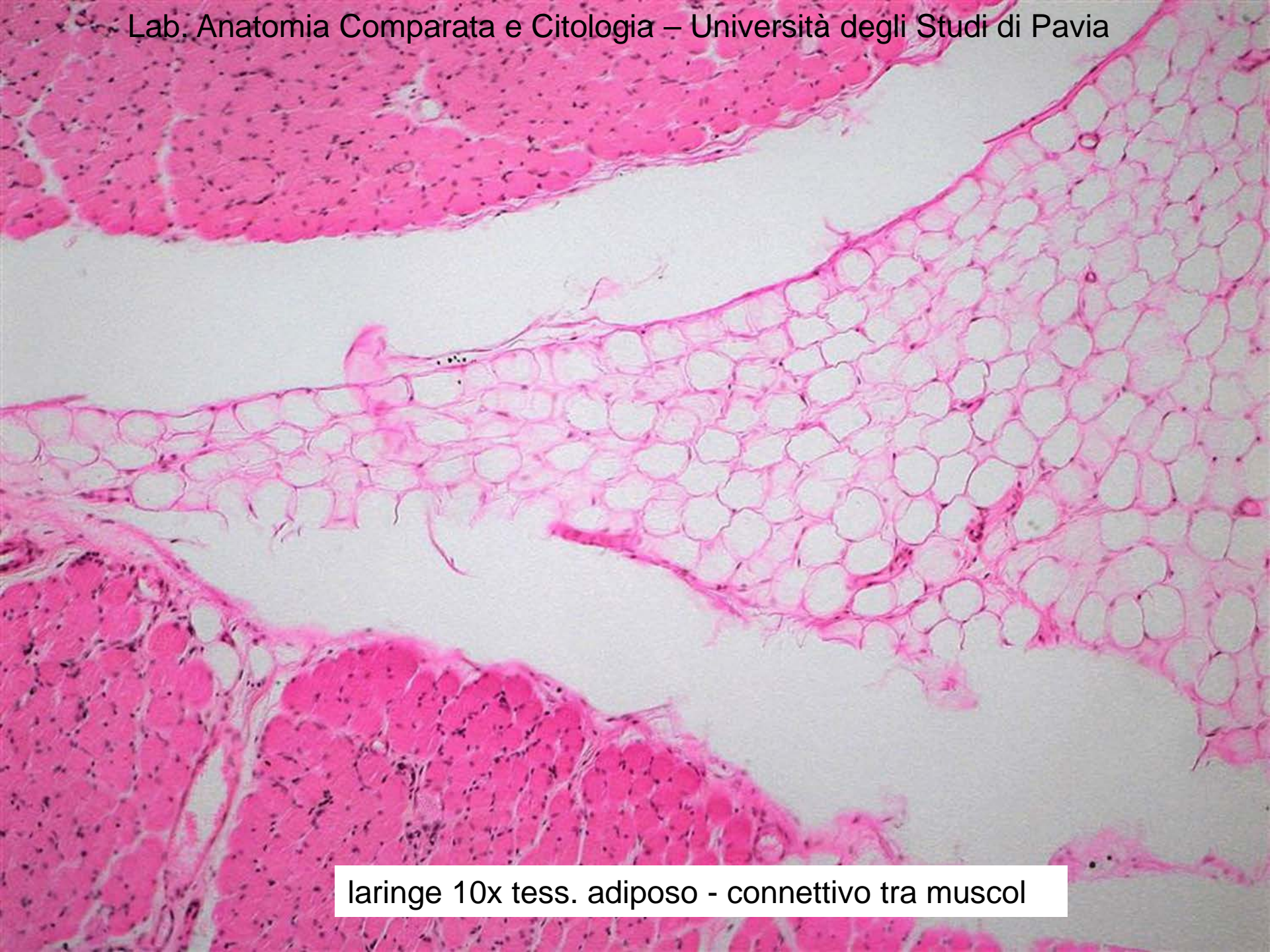
laringe 10x musc-connett-epit vocale pavimentoso



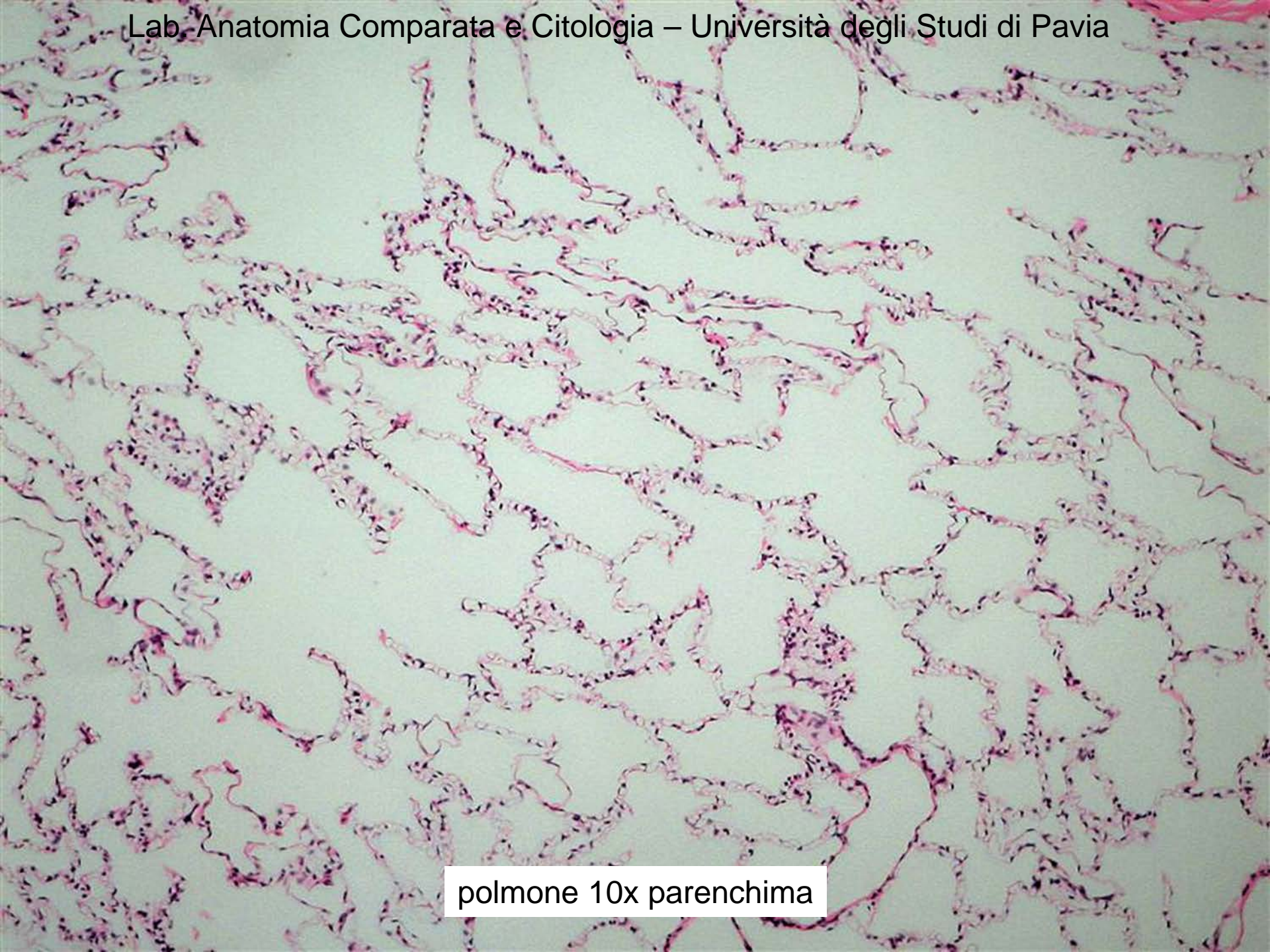
laringe 20x particol epit vocale pavement pluristrat



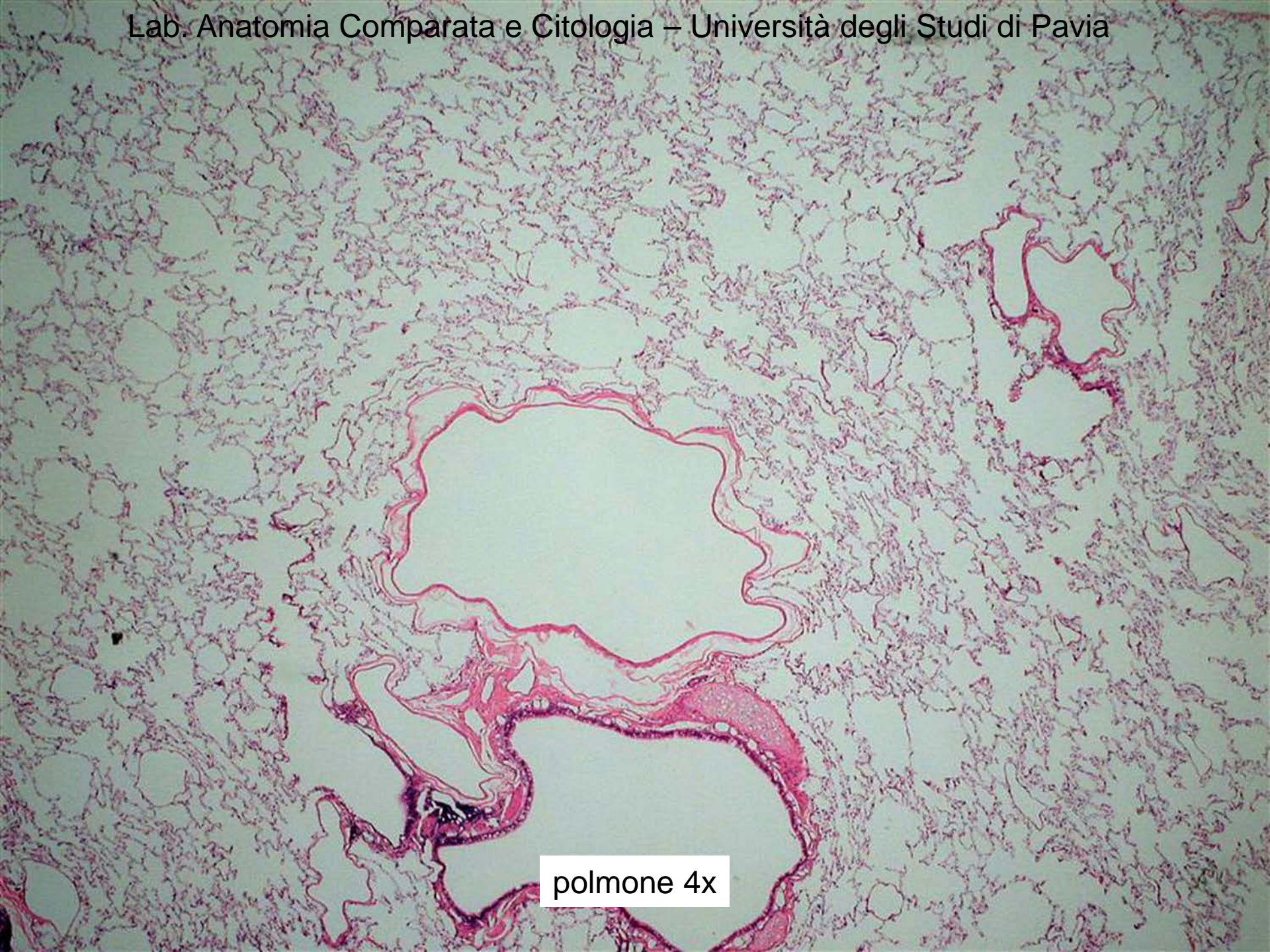
laringe 40x particolare epit vocale pavement pluristrat



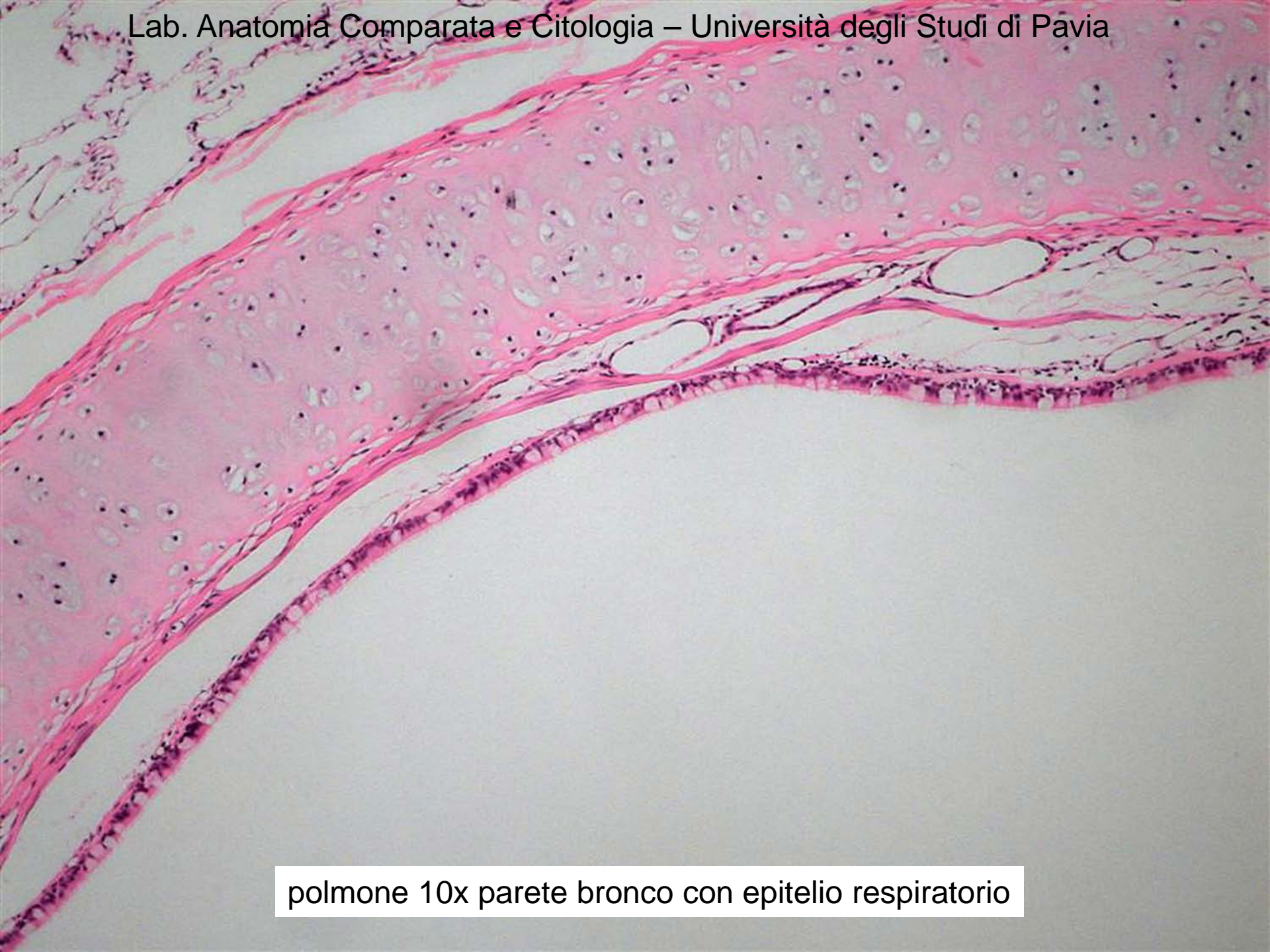
laringe 10x tess. adiposo - connettivo tra muscol



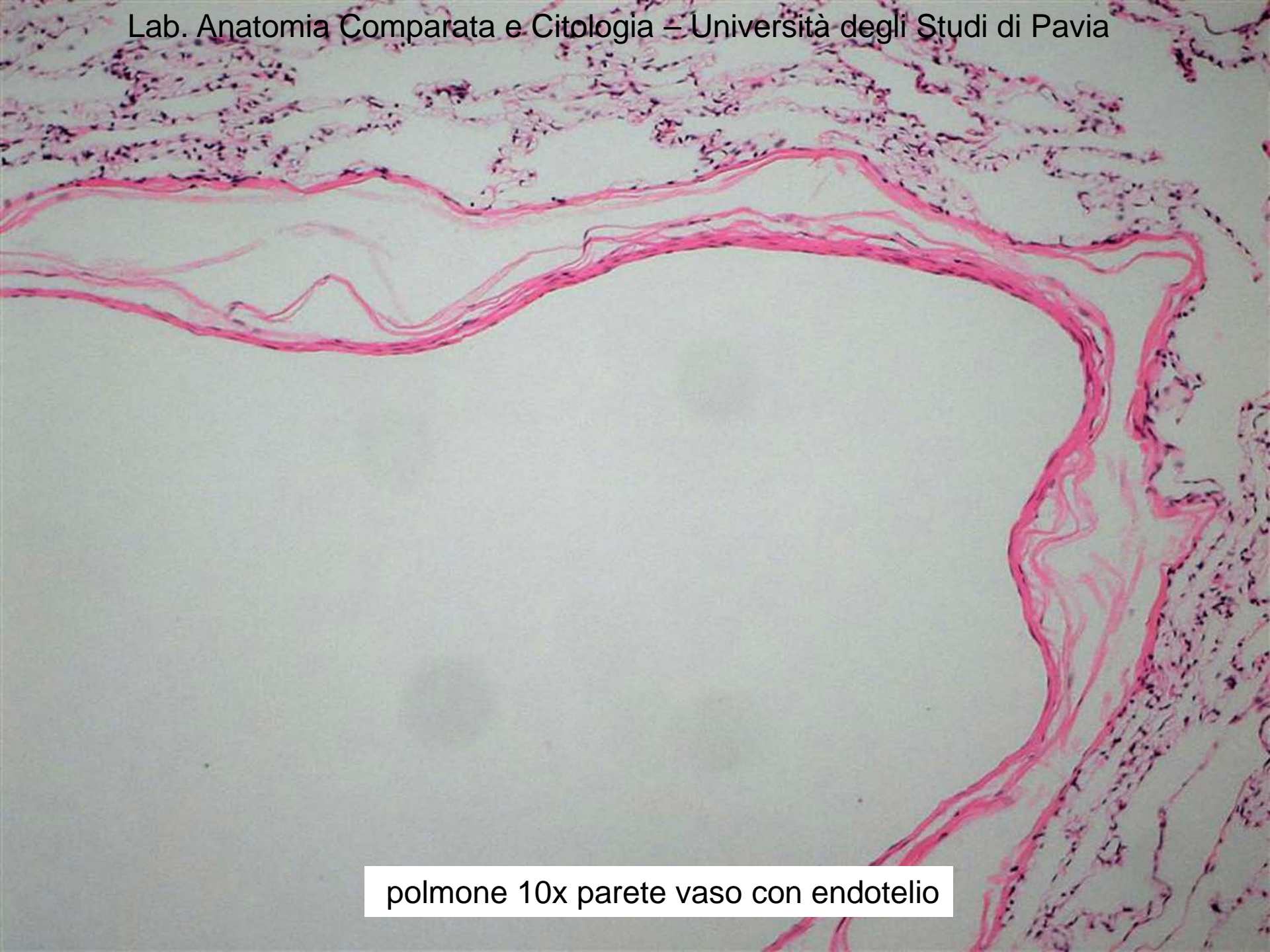
polmone 10x parenchima



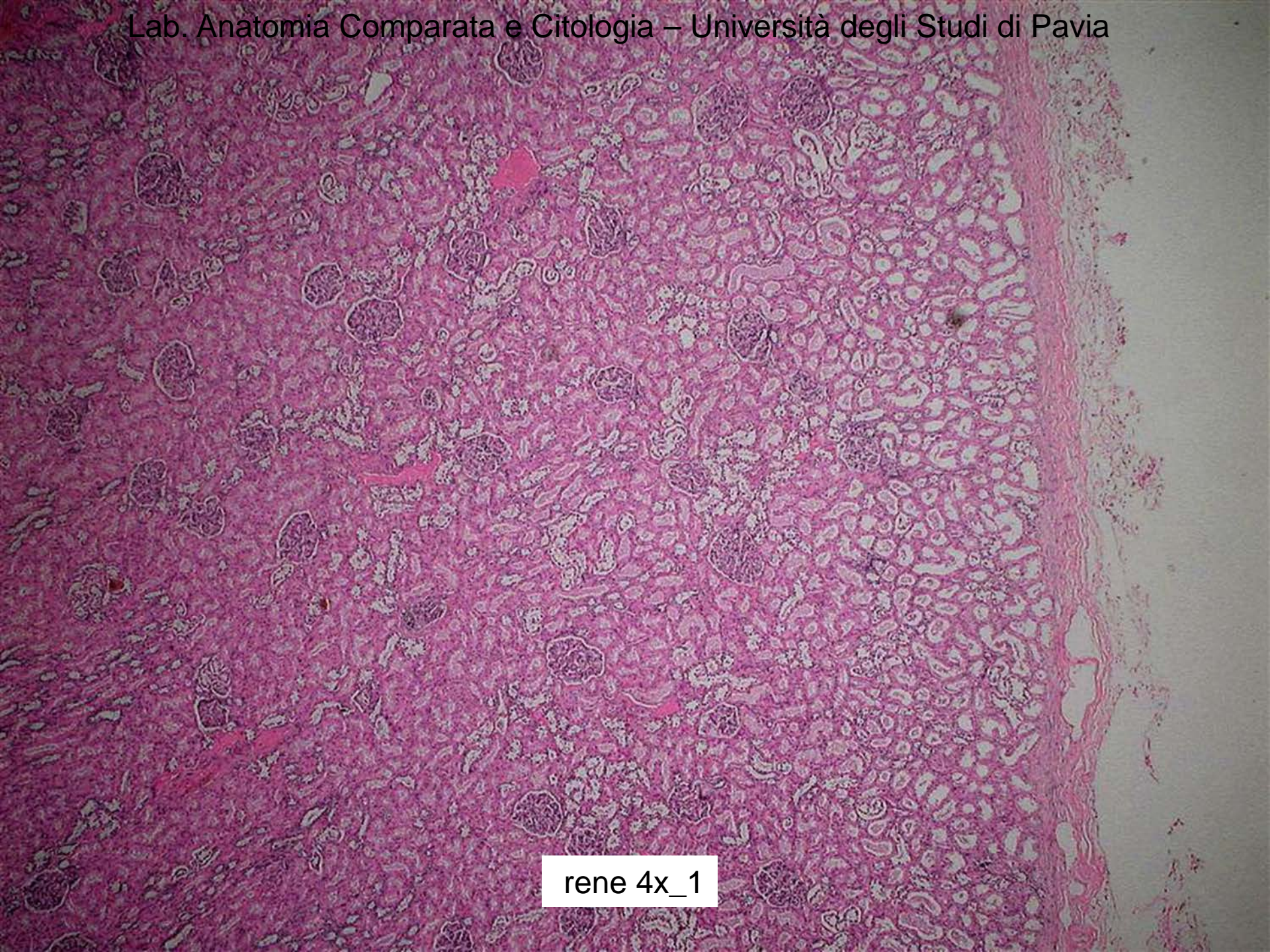
polmone 4x



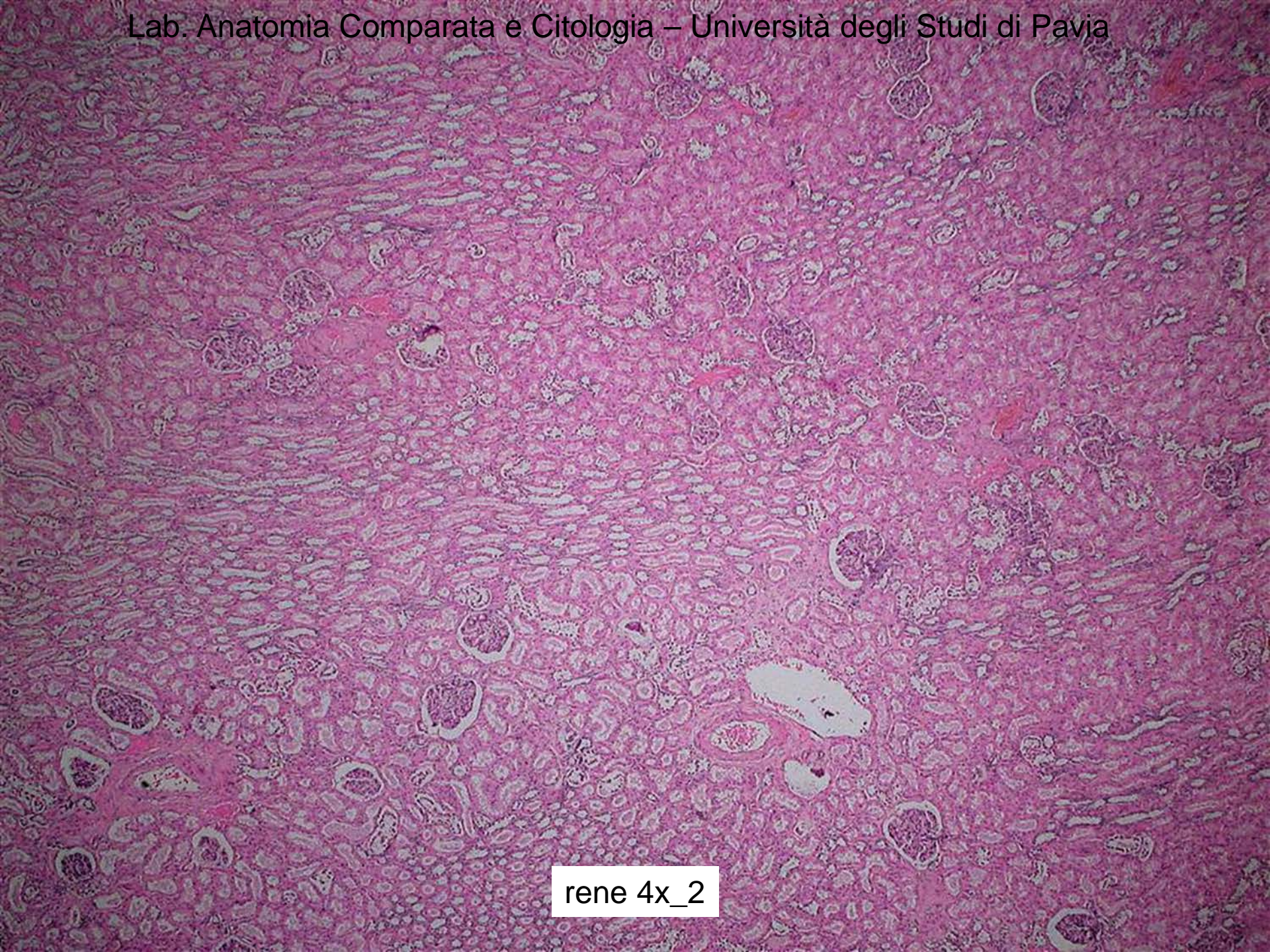
polmone 10x parete bronco con epitelio respiratorio



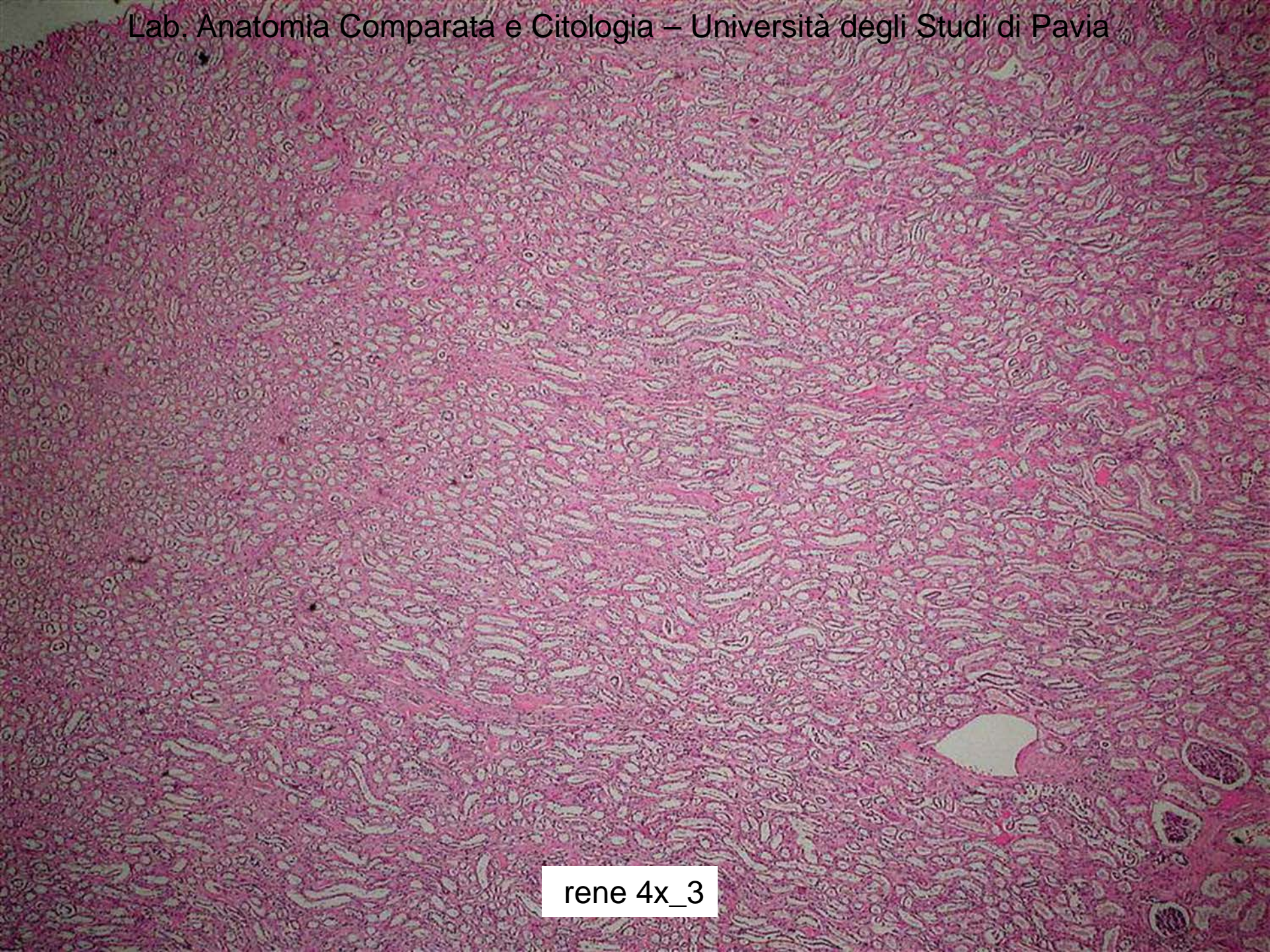
polmone 10x parete vaso con endotelio



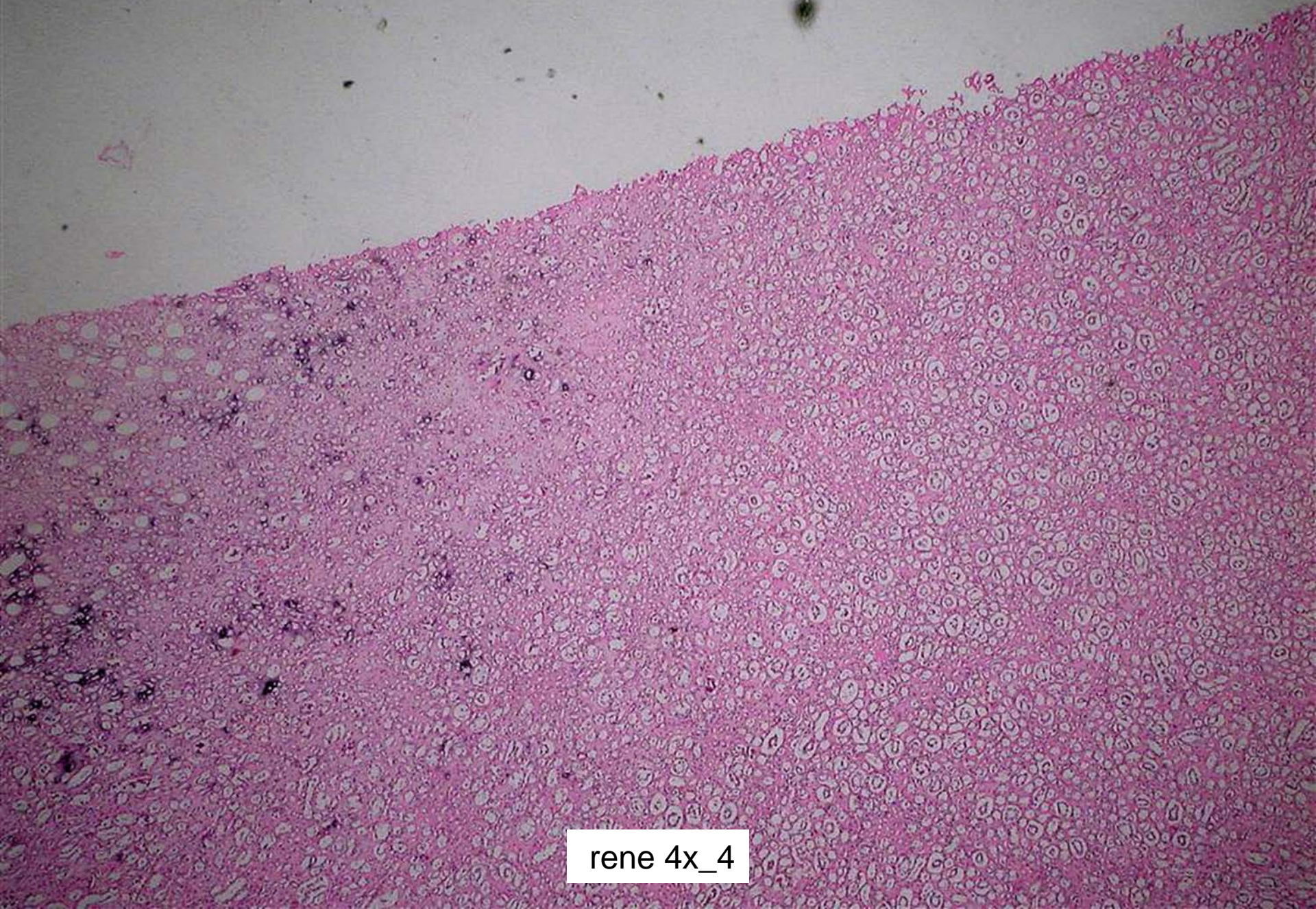
rene 4x_1



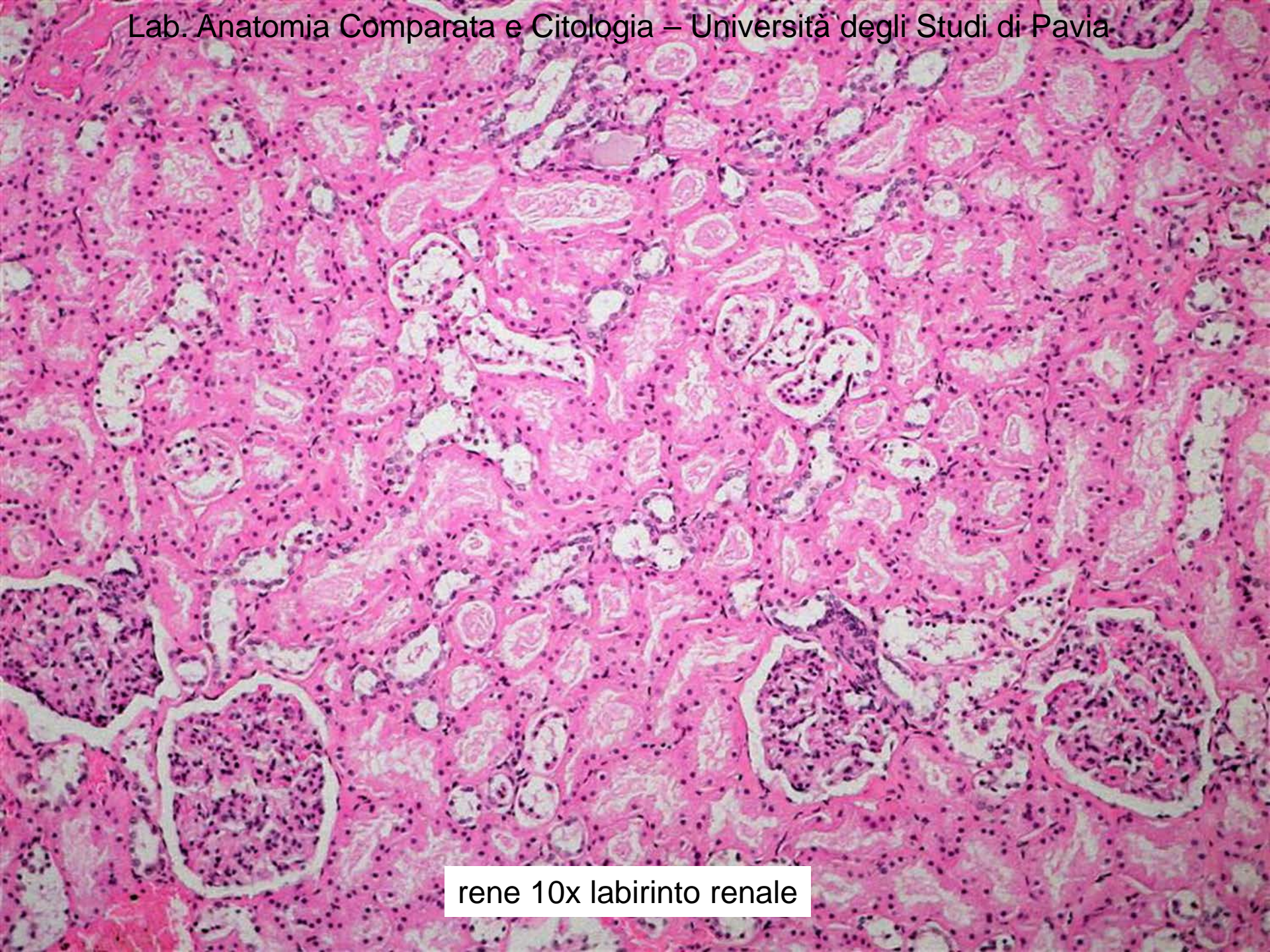
rene 4x_2



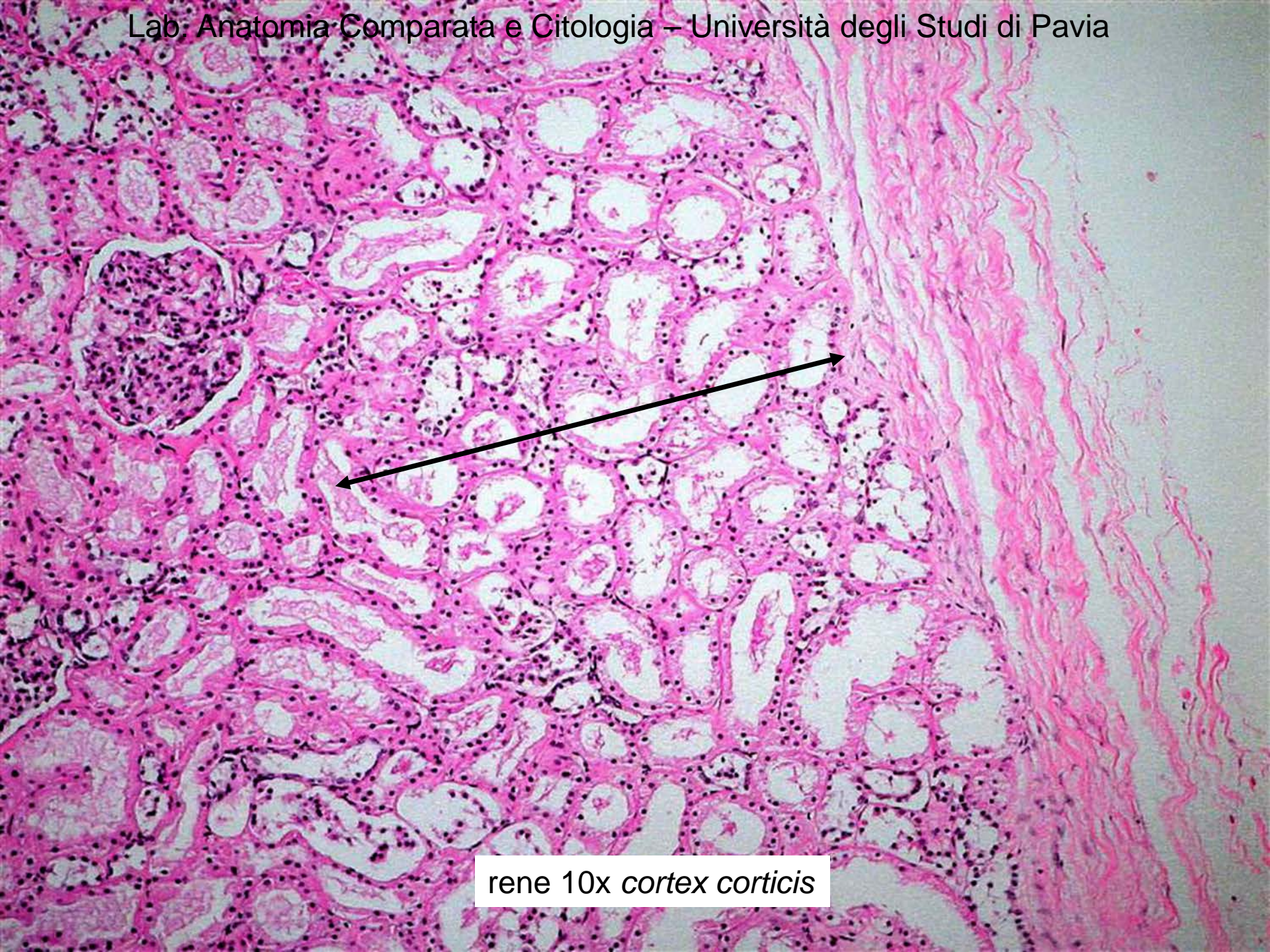rene 4x_3



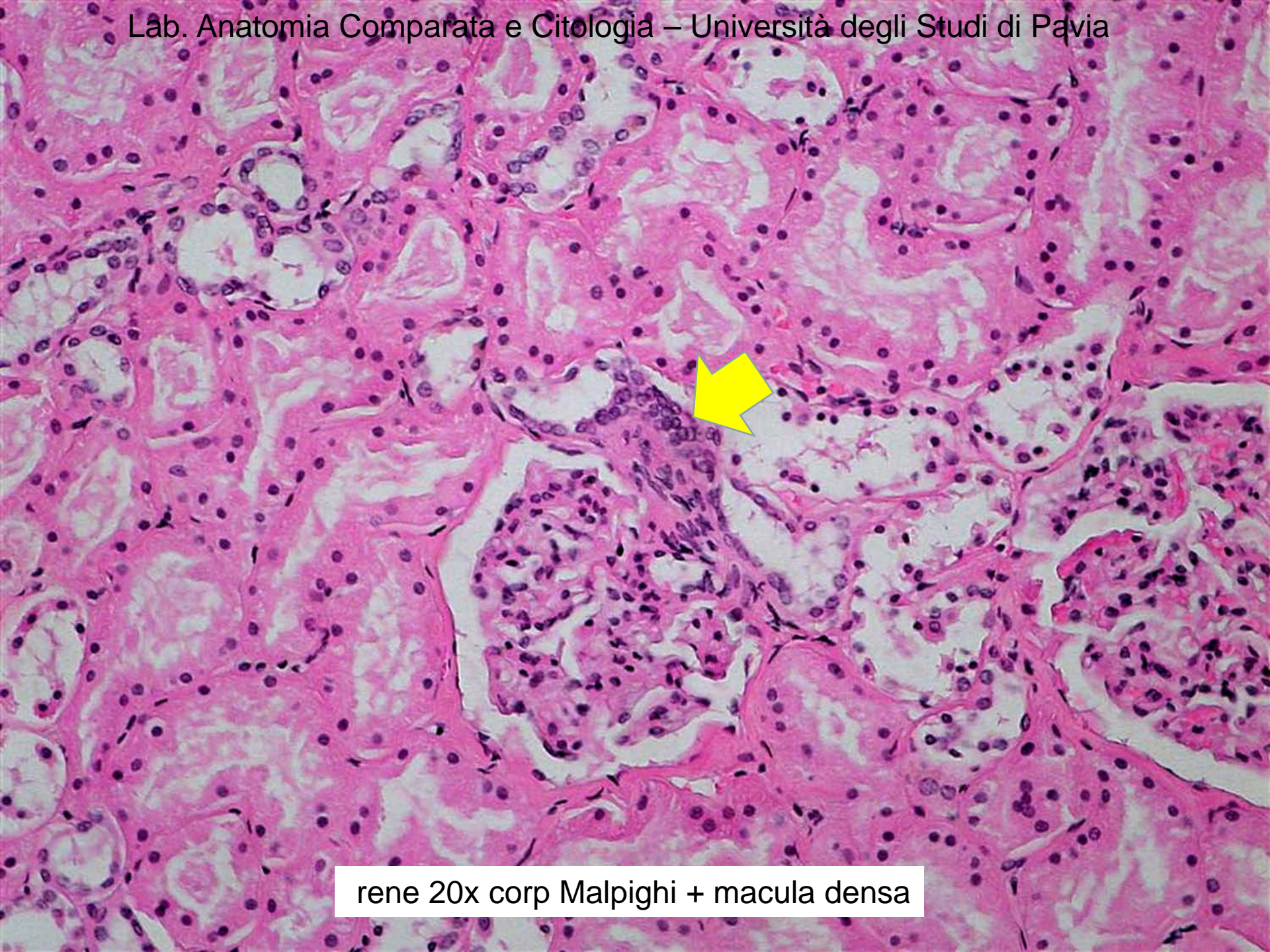
rene 4x_4



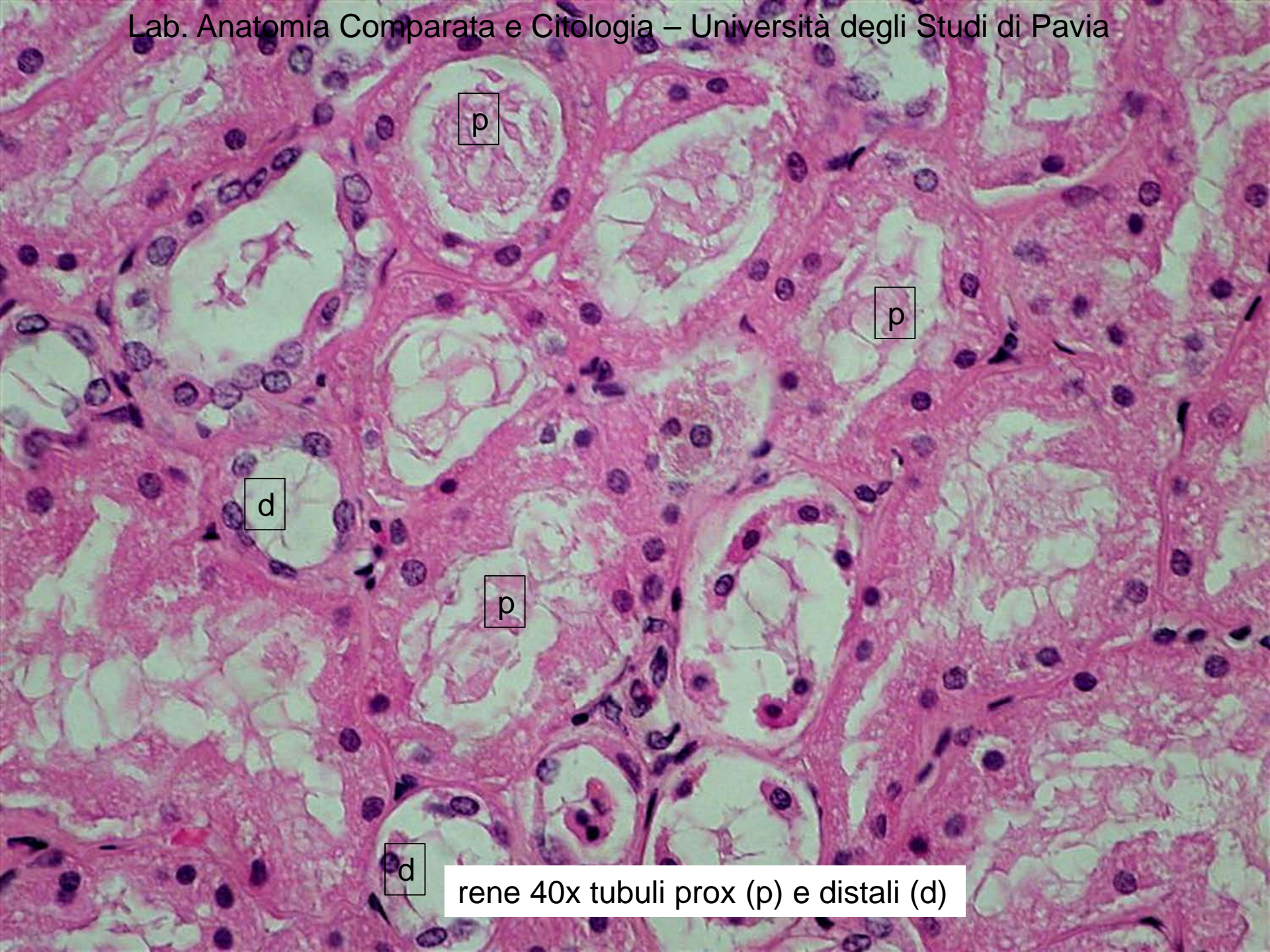
rene 10x labirinto renale



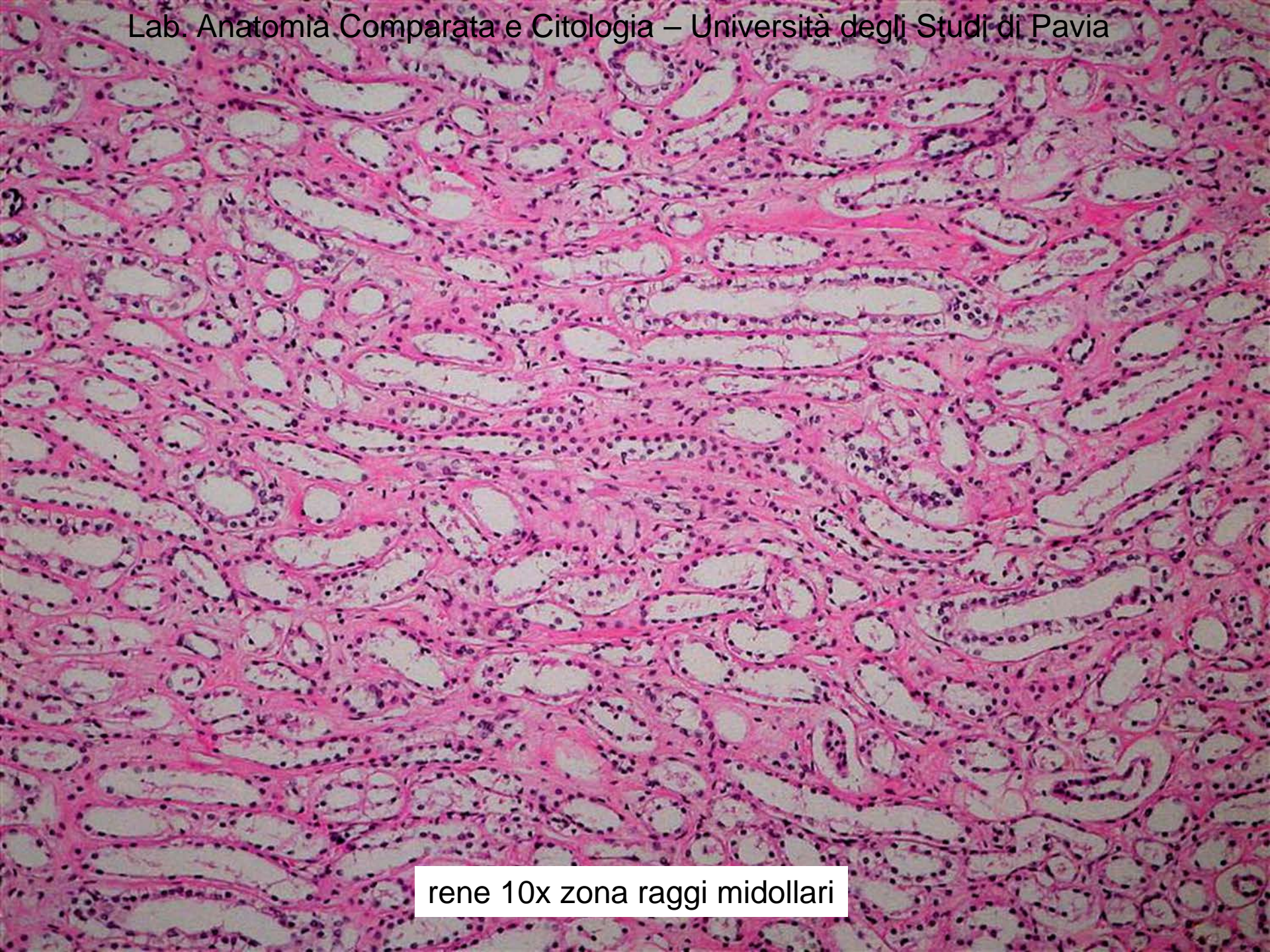
rene 10x cortex corticis



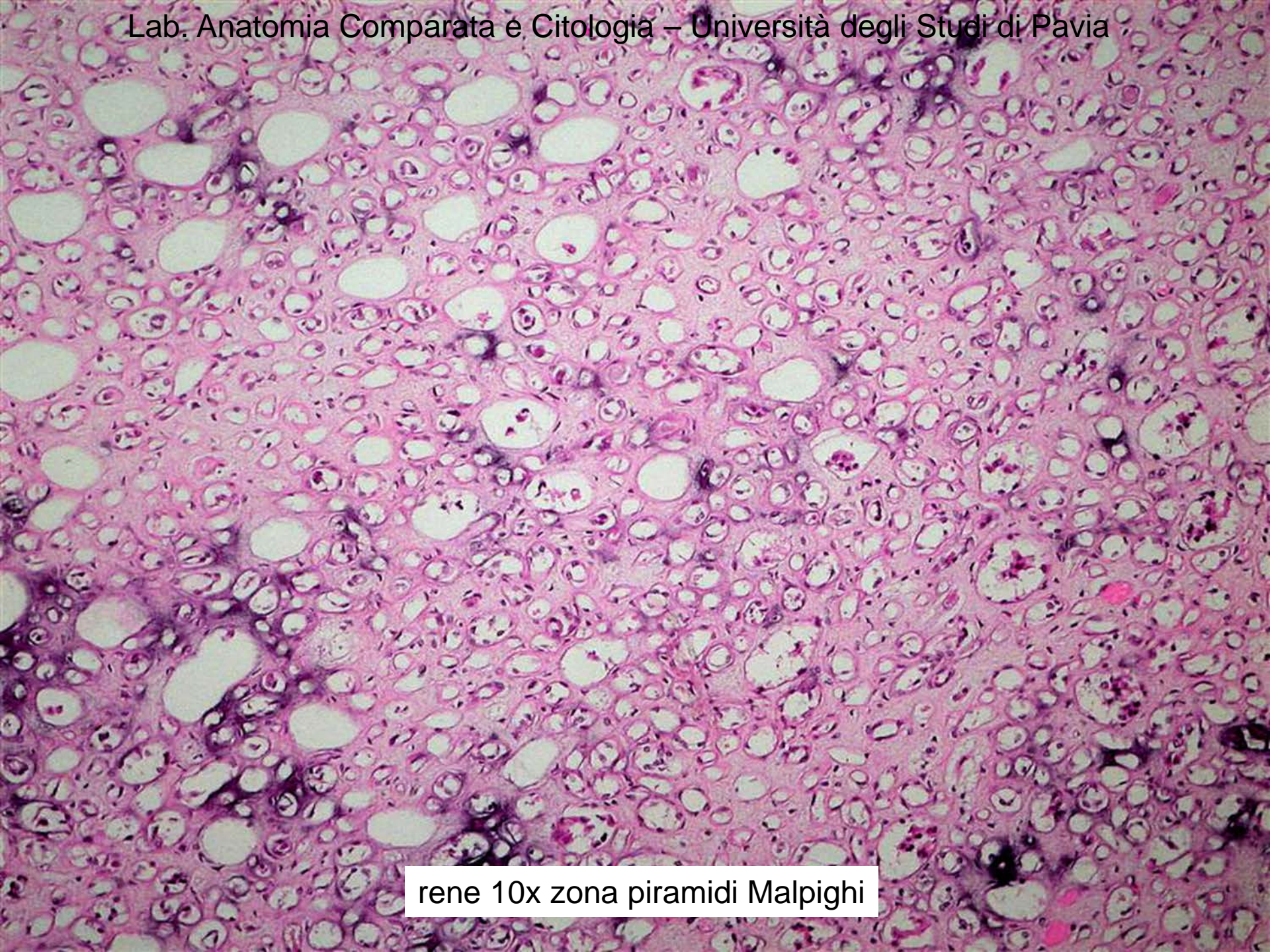
rene 20x corp Malpighi + macula densa



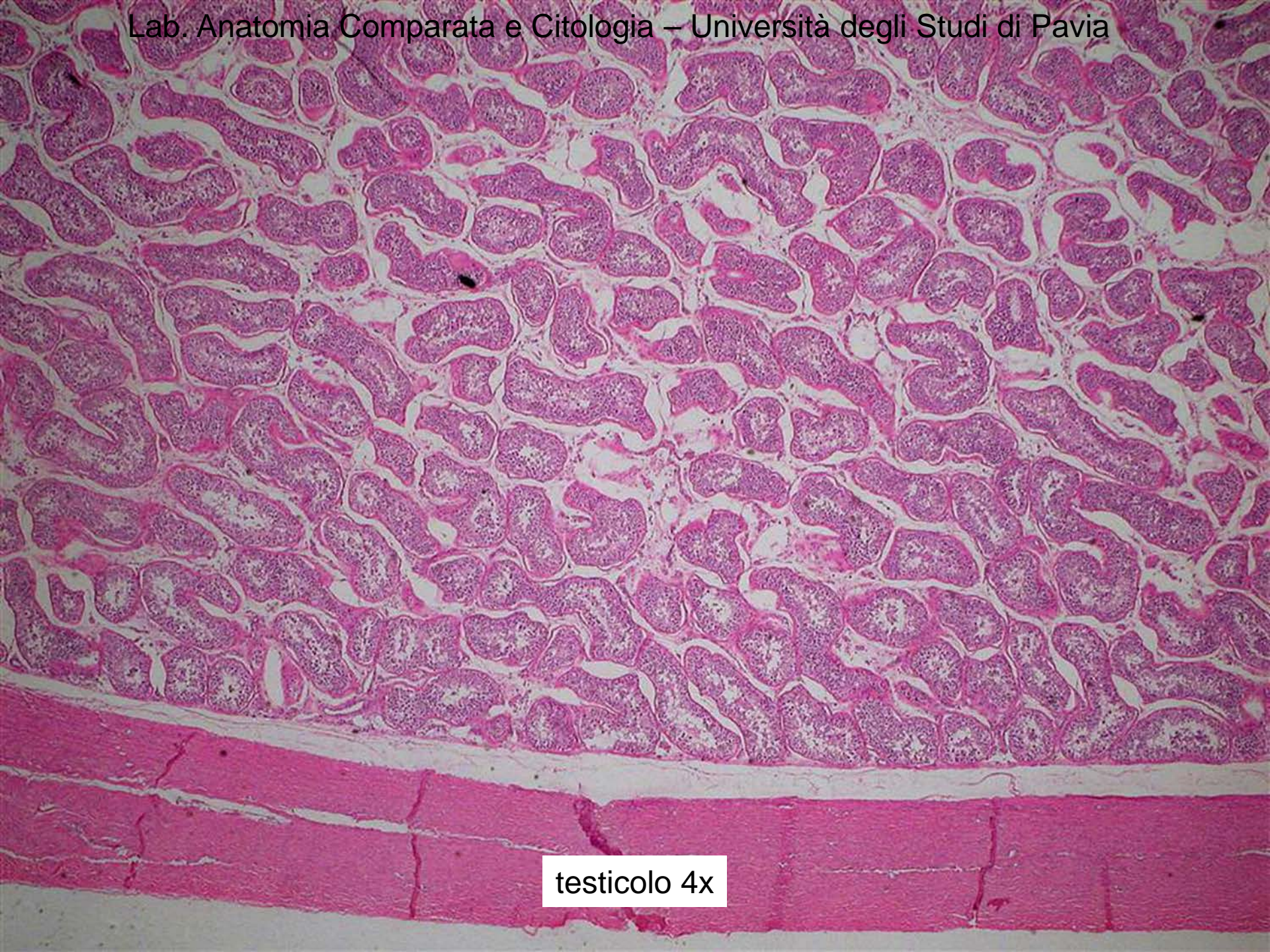rene 40x tubuli prox (p) e distali (d)



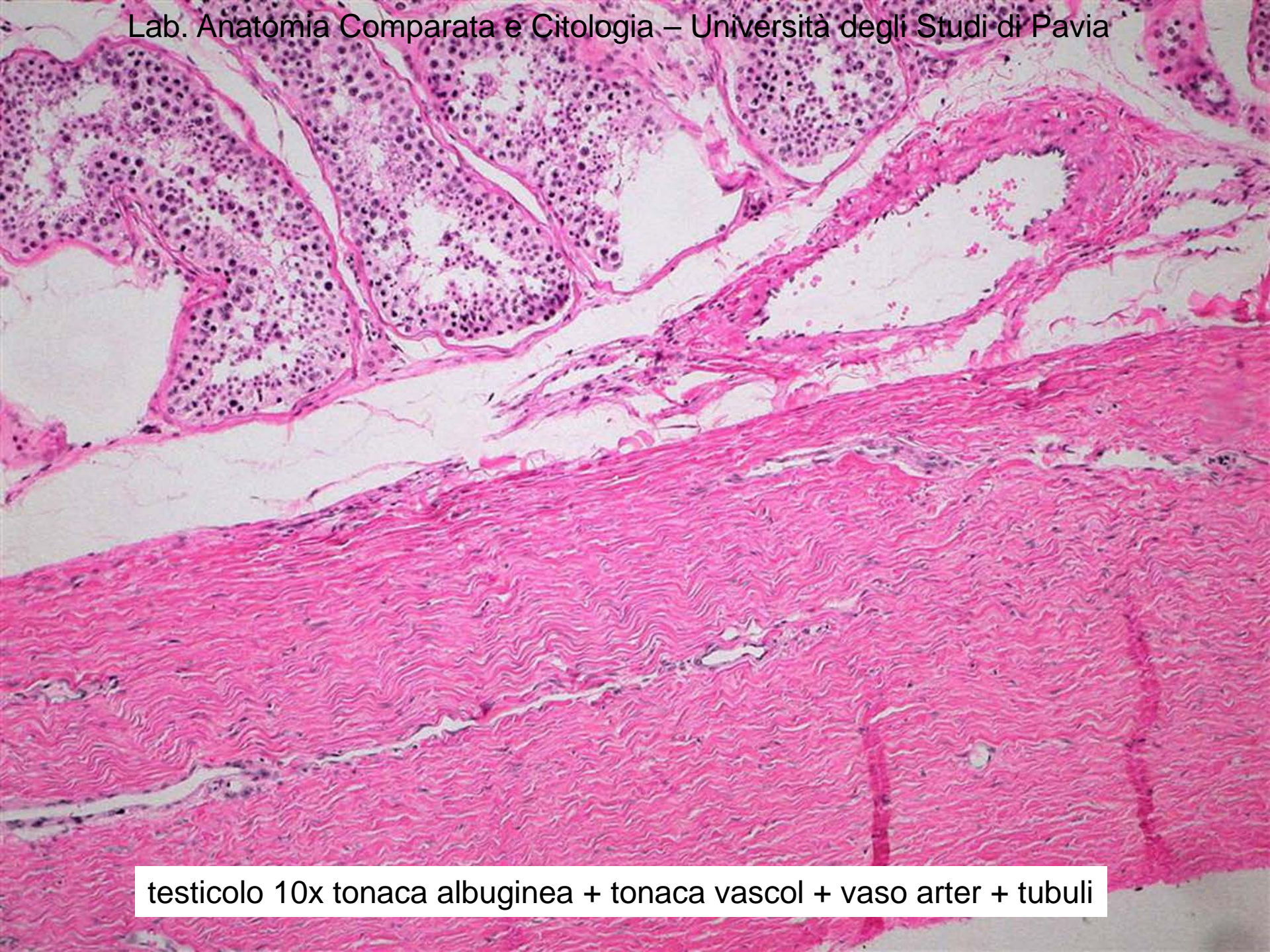
rene 10x zona raggi midollari



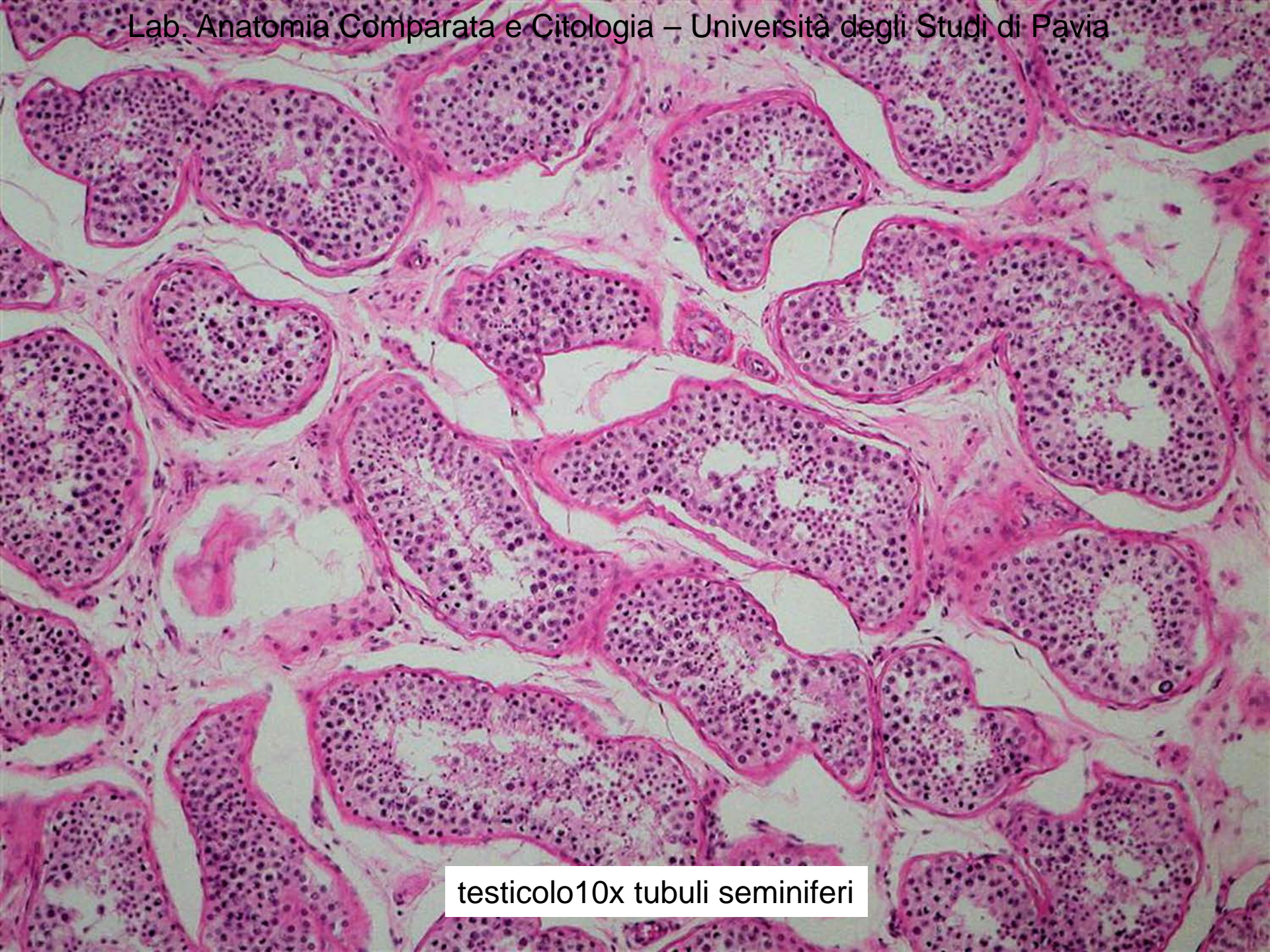
rene 10x zona piramidi Malpighi



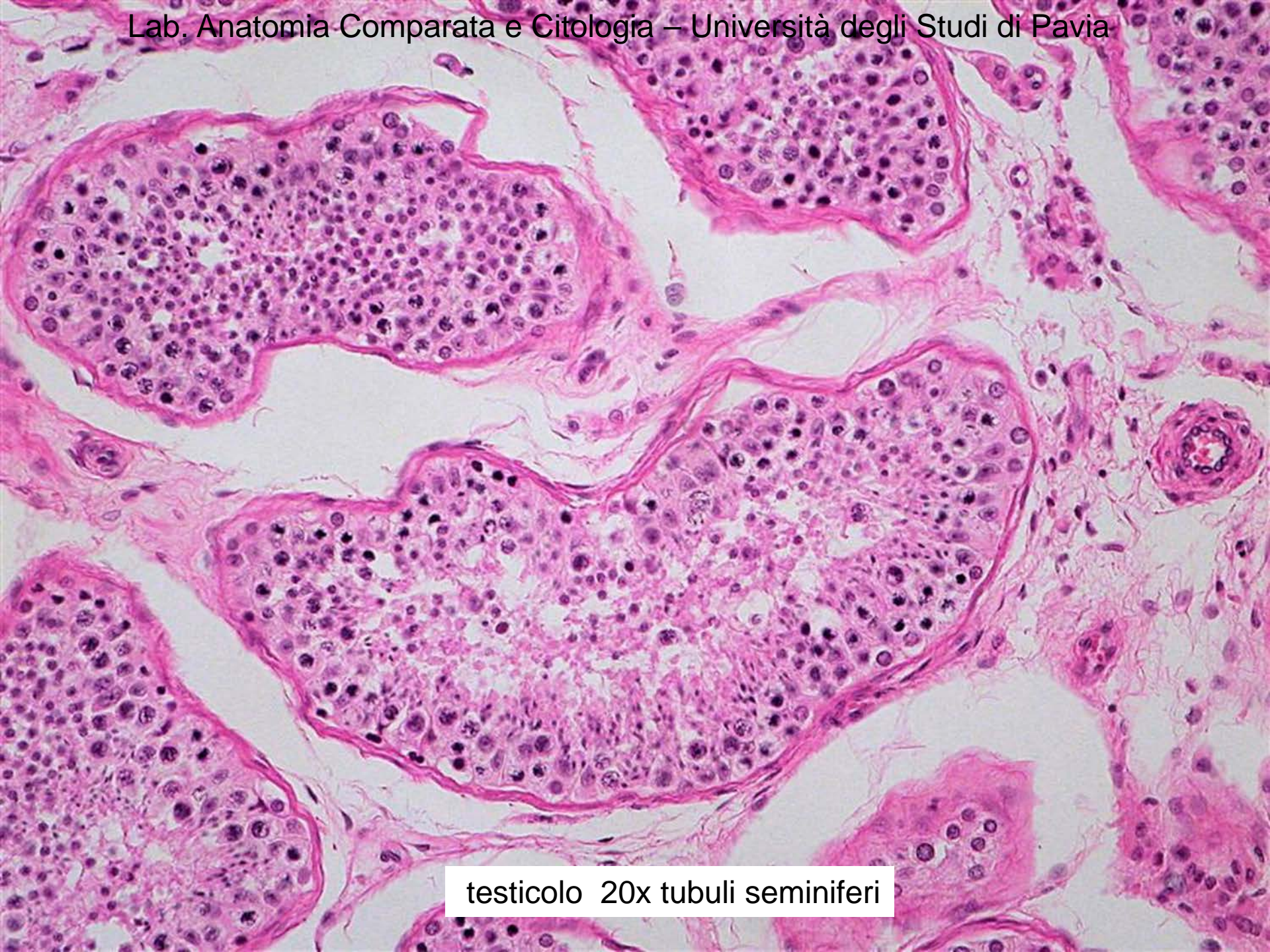testicolo 4x



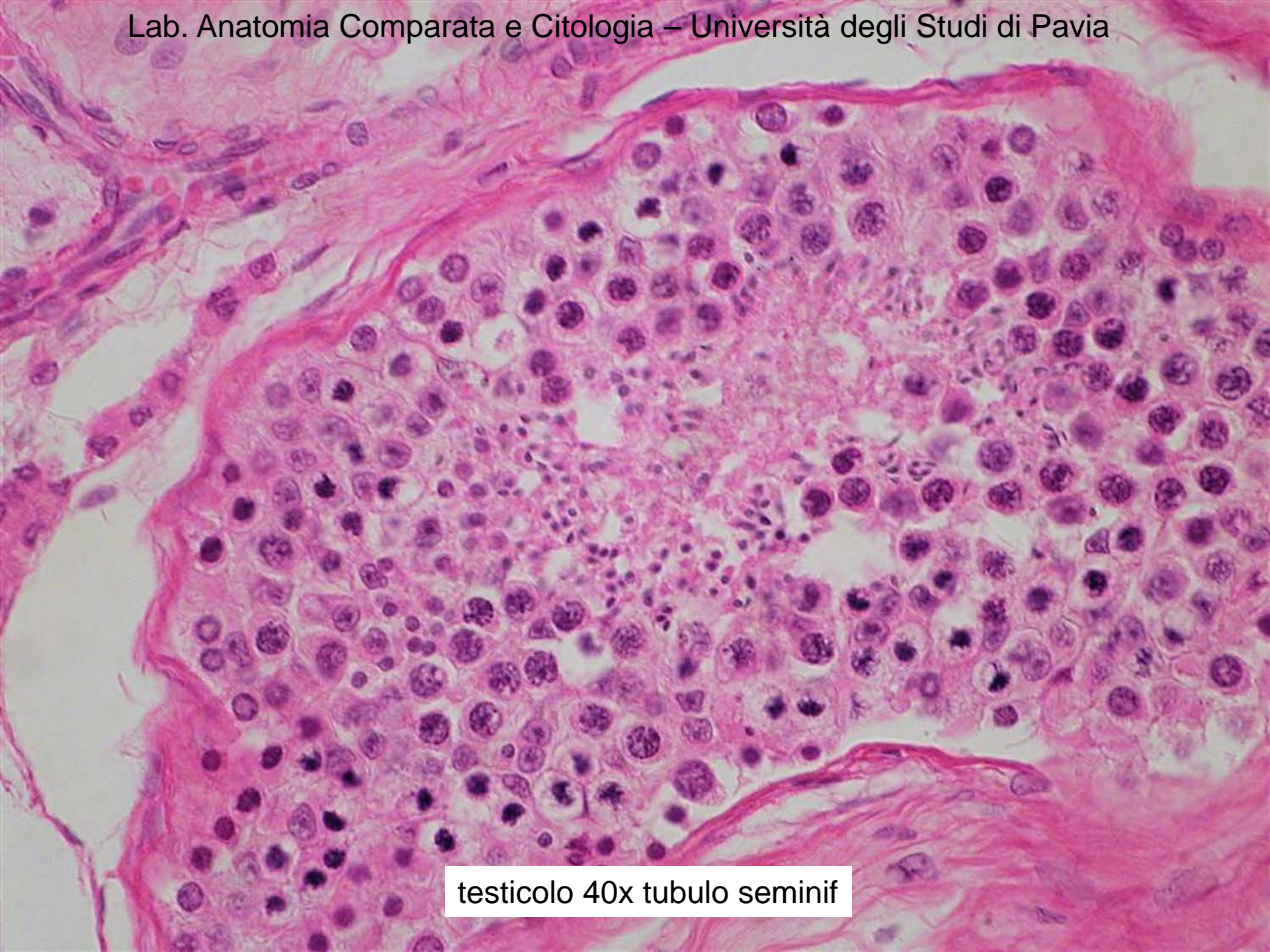
testicolo 10x tonaca albuginea + tonaca vascol + vaso arter + tubuli



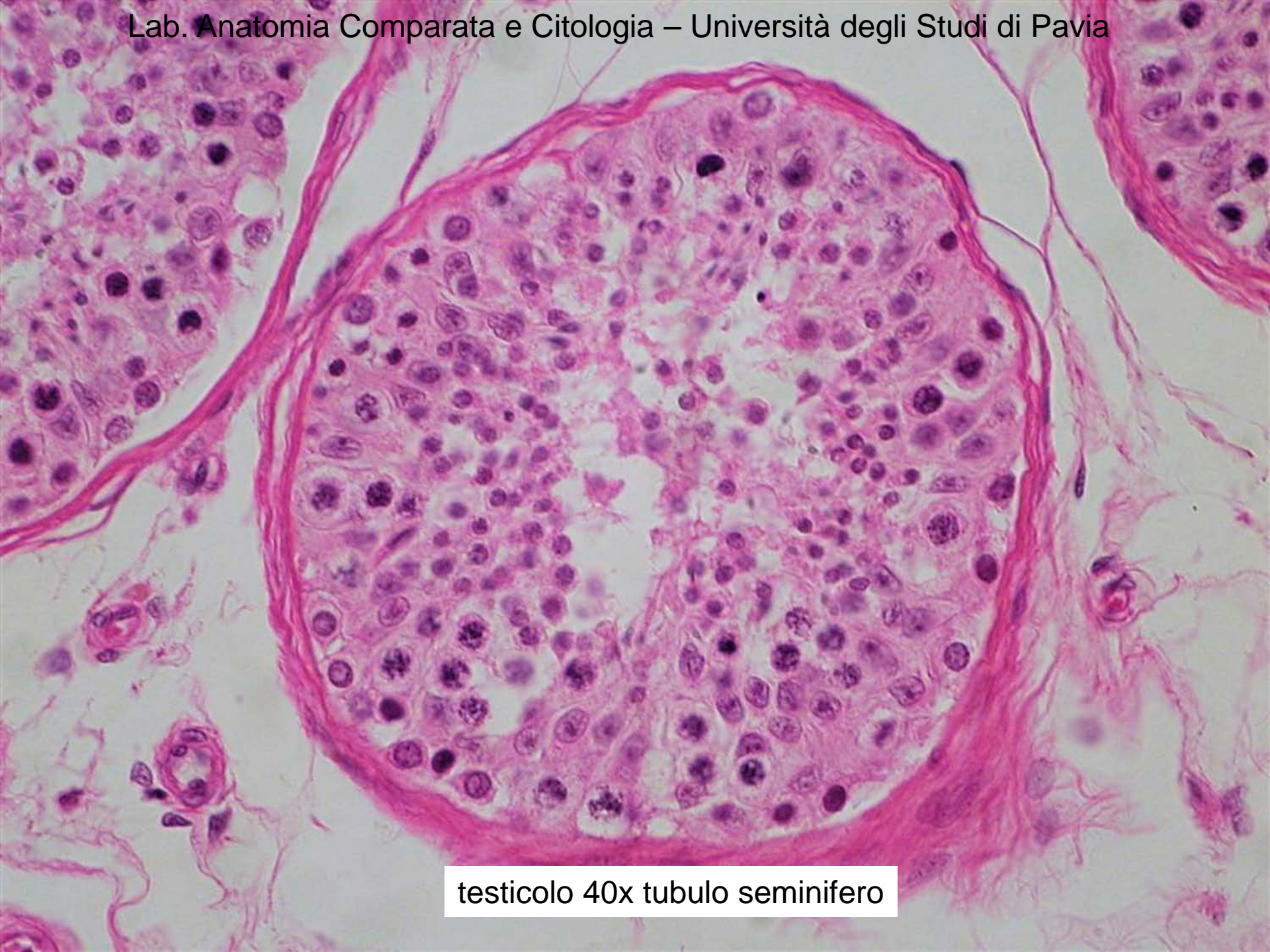testicolo10x tubuli seminiferi



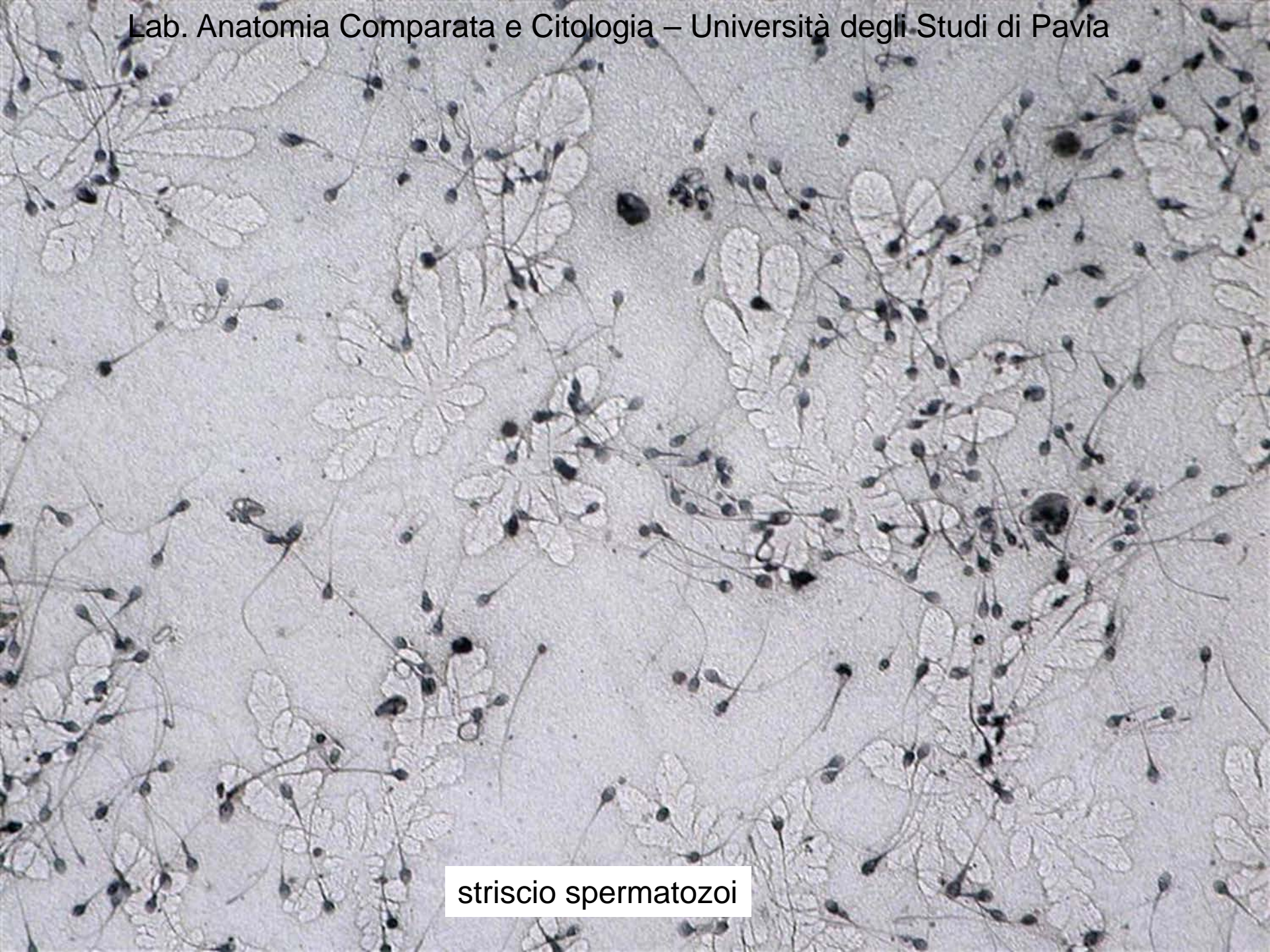
testicolo 20x tubuli seminiferi



testicolo 40x tubulo seminif



testicolo 40x tubulo seminifero



striscio spermatozoi